



Locally Advanced Cancer of the Ascending Colon - Laparoscopic Right Colectomy with Complete Mesocolic Excision

Antonio La Terra, Nicoletta Sveva Federico Pipitone, Patrizia Marsanic, Francesco Amico and Andrea Muratore*

Department of General Surgery, E. Agnelli Hospital, Pinerolo (TO), Italy

Abstract

Background: Complete Mesocolic Excision (CME) in colon cancer surgery seems to improve oncological outcome. CME is technically demanding with increased risks of vascular injury.

Study Design: a 51-year old female patient with a bulky cancer of the ascending colon undergoes a laparoscopic right colectomy with CME. The key-points of the CME procedure are shown in the video (<https://youtu.be/kKAKxZBLFDc>).

Technical Notes: A caudal-to-cranial and medial-to-lateral approach is used. Adequate dissection of the Toldt's plane, complete exposition of the superior mesenteric vein, and opening of the right part of the gastro-colic ligament with complete detachment of the duodenum-pancreas from the transverse mesocolon are the key-points to perform a safe CME.

Conclusion: At final pathology the stage of the cancer was pT3N1bM0 (3 positive lymph nodes out of 52 harvested). Postoperative stay was uneventful.

Keywords: Colon cancer; CME; Laparoscopy; Technique

OPEN ACCESS

*Correspondence:

Andrea Muratore, Department of General Surgery, E. Agnelli Hospital, Pinerolo (TO), Via Muratori 2C 10126 Turin, Italy, Tel: 39 3397351939; E-mail: amuratore67@icloud.com

Received Date: 30 Oct 2018

Accepted Date: 22 Nov 2018

Published Date: 27 Nov 2018

Citation:

La Terra A, Federico Pipitone NS, Marsanic P, Amico F, Muratore A. Locally Advanced Cancer of the Ascending Colon - Laparoscopic Right Colectomy with Complete Mesocolic Excision. *World J Surg Surgical Res.* 2018; 1: 1078.

Copyright © 2018 Andrea Muratore.

This is an open access article distributed under the Creative Commons Attribution License, which permits unrestricted use, distribution, and reproduction in any medium, provided the original work is properly cited.

Introduction

The concept of Complete Mesocolon Excision (CME) has been proposed for the first time in 2009 by Hohenberger [1]. The key points of CME are central tie of the artery supply and blunt dissection of the visceral plane from the retroperitoneal plane (along embryological planes) so to avoid any breaching of the visceral fascia which may lead to the spread of cancer cells on the peritoneal surface. CME is associated with a greater lymph node yield when compared with "standard surgery" [2]. For right sided cancers, CME procedures seems to be particularly indicated for cancers located in the ascending colon or hepatic flexure, seen their 4% to 8% rate of positive central lymph nodes (N3 lymph nodes according to the Japanese classification) [3]. However, definitive conclusions about the impact of CME on the long-term outcome cannot be drawn yet even if Hohenberger's group has recently reported an increased 5-year cancer-related survival rate in stage III colon cancers [4].

From a technical point of view, CME for cancers located in the ascending colon-hepatic flexure is complex since central ligation of the feeding arteries (ileocolic and middle colic arteries) requires complete exposition of the Superior Mesenteric Vein (SMV) and of the Henle trunk.

Aim of is paper is to present a procedure of laparoscopic right colectomy for a bulky ascending colon cancer focusing on the key-points of a CME procedure.

Case Presentation

On May 2018, a 51-year old healthy female patient was referred to the Department of General Surgery of our hospital due to a locally advanced cancer of the ascending colon just below the hepatic flexure. Carcinoembryonic and carbohydrate antigens were within the normal limits. Thoracic and abdomen dynamic contrast-enhanced computed tomography revealed a large tumor (9 cm in length) of the ascending colon with necrotic lymph nodes along the ileocolic and right colic arteries (Figure 1). There was no evidence of metastatic dissemination. Due to the young age, the location and stage of the cancer, a laparoscopic right colectomy with CME was planned.

Patient position and trocar sites

Under general anesthesia, the patient was placed in the supine position with the legs in stirrups.

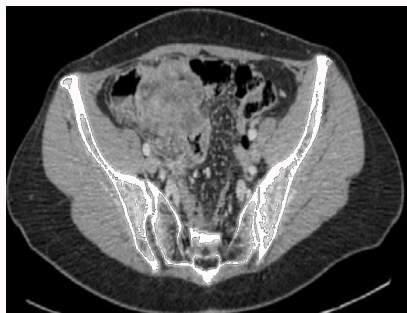

Figure 1: Bulky cancer of the ascending colon with enlarged regional necrotic lymph nodes.

The surgeon stood on the patient’s left, the camera operator on the left of the surgeon and the assistant on the patient’s right. The operative port position consisted of four sites: a 10 mm camera port, placed about 2 below the umbilicus on the midline; a 10 mm operative port, placed at the intersection of the left mid-clavicular line and the midpoint perpendicular to the diploid umbilical line; two 5 mm assistant operating ports, placed at the intersection of the left mid-clavicular line and the anterior superior iliac spines line and about 3 cm below the costal margin on the right mid-clavicular line (Figure 2).

A caudal-to-cranial and medial-to-lateral approach was used. As first step, the ileocolic vessels were identified and the mesentery opened along the inferior edge of these vessels to the left of the superior mesenteric artery. The Todt’s space was then entered under the ileocolic vessels and initially dissected so to detach the pancreas-duodenum from the mesocolic plane. Then, the dissection was carried on along the right edge of the Superior Mesenteric Artery (SMA) with complete exposition of the Superiore Mesenteric Vein (SMV) and isolation of the root of the Ileocolic Vein (ICV) which was clipped and sectioned. Cranial to the root of the ICV and along the right edge of the SMV, the origin of the Ileo-colic Artery (ICA), of the right colic vein, and of the right colic artery were isolated, clipped and sectioned.

After following the inferior edge of the ileocolic vessels from medial to lateral and stapling the distal ileum, the dissection is carried on cranially toward the transverse mesocolon along the anterior surface of the SMV in order to identify the origin of the middle colic vessels. The opening, at this time of the operation, of the gastro-colic ligament from medial to lateral (toward the hepatic flexure) allows to completely detach the duodenum from the transverse mesocolon and to free the root of the middle colic vessels which can now be approached safely and sectioned at the origin. Moreover, since the higher risk of lymph node metastases at the infrapyloric group in the subset of cancers located in the ascending-hepatic flexure colon, the dissection runs along the inferior edge of the duodenum and the right gastro-epiploic vessels are sectioned at the origin (number 6 group lymph nodes).

Final steps were the stapling of the transverse colon and the opening of the right lateral paracolic gutter. A 5 cm median abdominal incision was made at the site of the camera port and the specimen was extracted through a protection sleeve. An extracorporeal side-to-side ileum-colon anastomosis was performed.

Final pathology and outcome

Final pathology revealed a poorly-differentiated colon adenocarcinoma pT3N1b (according to the 8th edition TNM

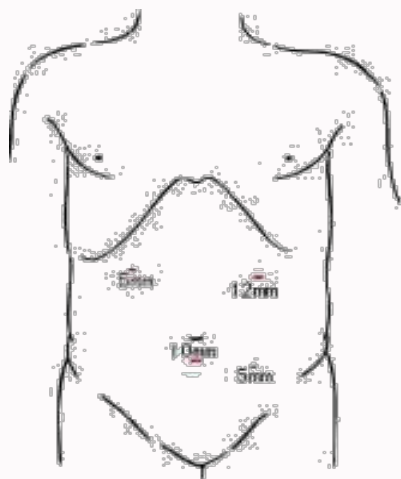


Figure 2: Trocar position.

classification). Metastases were present in 3 out of 52 lymph nodes. Distal and radial margins were negative.

Postoperative stay was uneventful. The patient was discharged 6 days postoperatively and was started on oxaliplatin-basec chemotherapy 30 days after surgery.

Discussion

Since the start of routine application of Total Mesorectal Excision (TME) for mid-low rectal cancers, long-term outcome of such patients has significantly improved [5]. In fact sharp dissection of the embryological plane between the mesorectal and pelvic fascia produces an intact fascial-lined rectal specimen. The grade of completeness of TME has been shown to be an independent prognostic factor of local recurrence [6]. The concept of CME for colon cancer is similar to TME for rectal cancer and is based on complete removal of the mesocolon containing colonic vascular and lymphatic drainage [1]. A grading system of the quality of colon surgery has shown before an association between CME and long-term survival, especially for stage III cancers [7].

For left-sided colon cancers there is not so much difference between “standard” surgery and CME since most surgeons perform a high-tie ligation of the inferior mesenteric artery together with a complete mesocolic excision. However, for right-sided colon cancers (especially hepatic flexure cancers), vascular ligation of the arterial supply is usually at the level of D2 [8]. Many discrepancies can be found in guidelines on this. The European Society of Medical Oncology guidelines focus more on the overall number of lymph nodes yield at finale pathology rather than on the level of the dissection. The American Society of Colon and Rectal Surgeons guidelines, do not advocate routine CME procedures for colon cancers despite highlighting the need to remove cancer feeding vessels at their origin [8,9]. On the contrary, Japanese guidelines recommend CME (D3 dissection) for stage II to III colorectal cancers [10].

The number of harvested lymph nodes is surely increased after CME procedures: specimens from 49 CME procedures were compared with 40 non-CME ones by Leeds’ group in 2009 [2]; more lymph nodes were retrieved in the CME group (p<0.001) for both right and left-sided resections. Similar results were recently shown by Ouchi [11] comparing 178 patients undergone a D2 dissection with 533 undergone a D3 dissection (CME). For right-sided colon cancers,

cancers located in the ascending colon, hepatic flexure/proximal transverse colon seem to be the best indication to CME procedures with central ligation of the middle colic artery because of the up to 8% rate of lymph node metastases in station 223 [3,12].

Unfortunately, the advantages in terms of long-term outcome are not so clear. The better 5-year cancer-related survival and of loco-regional recurrence rates shown by both Hohenberger's [4] and Ouchi's group [11] with the adoption a CME procedure have not been confirmed in other studies [13,14]. Stage migration in CME patients by the higher lymph node yield achieved might play a role in the improved survival of these patients. The survival advantage seems to be more evident in stage III colon cancer patients than in stage I-II [4,15].

Right colectomy with CME, either open or laparoscopic is technically demanding. The laparoscopic approach seems to achieve similar short-term oncological results without increased morbidity rates [16,17]. In particular, these results were obtained by supervised surgical trainees suggesting that CME technique is reproducible [17]. However, implementation of CME procedures increases the morbidity rates as recently reported by the Erlangen's group [4]. Bertelsen [18] has compared 529 patients undergone CME colon cancer surgery vs. 1,701 patient's undergone "conventional" surgery: morbidity rates were comparable whereas increased rates of injury to other organs, in particular to the superior mesenteric vein, were found.

In conclusion, patients with ascending-hepatic flexure colon cancers seem to represent the best indication to a laparoscopic right colectomy with CME. The CME procedure is technically demanding and should be performed by skilled laparoscopic colorectal surgeons.

References

- Hohenberger W, Weber K, Matzel K, Papadopoulos T, Merkel S. Standardized surgery for colonic cancer: complete mesocolic excision and central ligation - technical notes and outcome. *Colorectal Dis.* 2009;11(4):354-64.
- West NP, Hohenberger W, Weber K, Perrakis A, Finan PJ, Quirke P. Complete mesocolic excision with central vascular ligation produces an ontologically superior specimen compared with standard surgery for carcinoma of the colon. *J Clin Oncol.* 2009;28(2):272-8.
- Bertelsen CA, Kirkegaard-Klitbo A, Nielsen M, Leotta SM, Daisuke F, Gögenur I. Pattern of colon cancer lymph node metastases in patients undergoing central mesocolic lymph node excision: a systematic review. *Dis Colon Rectum.* 2016;59(12):1209-21.
- Merkel S, Weber K, Matzel KE, Agaimy A, Göhl J, Hohenberger W. Prognosis of patients with colonic carcinoma before, during and after implementation of complete mesocolic excision. *Br J Surg.* 2016;103(9):1220-9.
- Wibe A, Møller B, Norstein J, Carlsen E, Wiig JN, Heald RJ, et al. A national strategic change in treatment policy for rectal cancer-implementation of total mesorectal excision as routine treatment in Norway: a national audit. *Dis Colon Rectum.* 2002;45(7):857-66.
- Quirke P, Steele R, Monson J, Grieve R, Khanna S, Couture J, et al. Effect of the plane of surgery achieved on local recurrence in patients with operable rectal cancer: a prospective study using data from the MRC CR07 and NCIC-CTG CO16 randomized clinical trial. *Lancet.* 2009;373(9666):821-8.
- West NP, Morris EJ, Rotimi O, Cairns A, Finan PJ, Quirke P. Pathology grading of colon cancer with survival: a retrospective observational study. *Lancet Oncol.* 2008;9(9):857-65.
- Pellino G, Warren O, Mills S, Rasheed S, Tekkis PP, Kontovounisios C. Comparison of western and asian guidelines concerning the management of colon cancer. *Dis Colon Rectum.* 2018;61(2):250-9.
- Schmoll HJ, Van Cutsem E, Stein A, Valentini V, Glimelius B, Haustermans K, et al. ESMO consensus guidelines for management of patients with colon and rectal cancer. A personalized approach to clinical decision making. *Ann Oncol.* 2012;23(10):2479-516.
- Ishiguro M, Higashi T, Watanabe T, Sugihara K; Japanese Society for Cancer of the Colon and Rectum Guideline Committee. Changes in colorectal cancer care in Japan before and after guideline publication: a nationwide survey about D3 lymph node dissection and adjuvant chemotherapy. *J Am Coll Surg.* 2014;218(5):969-77.
- Ouchi A, Komori K, Kimura K, Kinoshita T, Shimizu Y, Nagino M. Survival benefit of japanese extended lymphadenectomy for clinically node-negative and node-positive colorectal cancers. *Dis Colon Rectum.* 2018;61(2):162-71.
- Park IJ, Choi GS, Kang BM, Lim KH, Jun SH. Lymph node metastasis patterns in right-sided colon cancers: is segmental resection of these tumors ontologically safe? *Ann Surg Oncol.* 2009;16(6):1501-6.
- Olofsson F, Buchwald P, Elmståhl S, Syk I. No benefit of extended mesenteric resection with central vascular ligation in right-sided colon cancer. *Colorectal Dis.* 2016;18(8):773-8.
- Hashiguchi Y, Hase K, Ueno H, Mochizuki H, Shinto E, Yamamoto J. Optimal margins and lymphadenectomy in colonic cancer surgery. *Br J Surg.* 2011;98(8):1171-8.
- Chow CFK, Kim SH. Laparoscopic complete mesocolic excision: West meets East. *World J Gastroenterol.* 2014;20(39):14301-7.
- Storli KE, Sondenaa K, Furnes B, Eide GE. Outcome after introduction of complete mesocolic excision for colon cancer is similar for open and laparoscopic surgical treatments. *Dig Surg.* 2013;30(4-6):317-27.
- West NP, Kennedy RH, Magro T, Luglio G, Sala S, Jenkins JT, et al. Morphometric analysis and lymph node yield in laparoscopic complete mesocolic excision performed by supervised trainees. *Br J Surg.* 2014;101(11):1460-7.
- Bertelsen CA, Neuenschwander AU, Jansen JE, Kirkegaard-Klitbo A, Tenma JR, Wilhelmsen M, et al. Short-term outcome after complete mesocolic excision compared with conventional colonic cancer surgery. *Br J Surg.* 2016;103(5):581-9.