



Laparoscopic Splenectomy in Pregnancy – A Rescue Operation for Refractory Immune Thrombocytopenia: A Case Report

Thapar P^{1*}, Lakshmanan A¹, Bhurat N¹, Shah S¹, Kamat A², Naik A³, Gandhi S⁴ and Kapote S¹

¹Department of Minimal Invasive Surgery, Jupiter Hospital, Off Eastern Express Highway, India

²Department of Hematology, Jupiter Hospital, Off Eastern Express Highway, India

³Department of Anesthesia, Jupiter Hospital, Off Eastern Express Highway, India

⁴Department of Obstetrics, Jupiter Hospital, Off Eastern Express Highway, India

Abstract

Treatment options for Immune Thrombocytopenic Purpura (ITP) in pregnancy are limited, and splenectomy is reserved for refractory ITP. There is robust data on the safety of laparoscopic surgeries in pregnancy for other non-obstetric conditions. We report a case of refractory ITP successfully managed by Laparoscopic Splenectomy (LS) in a pregnant patient, thus, making the procedure a gold standard in such rare medical scenarios.

Keywords: Immune Thrombocytopenia Purpura; Laparoscopic splenectomy; Pregnancy

Introduction

Immune Thrombocytopenic Purpura (ITP) is an autoimmune disorder causing premature clearance of platelets in the spleen. The incidence of ITP is 1-2/10,000 pregnancies and accounts for 5% of cases of pregnancy associated with thrombocytopenia [1].

The literature review revealed limited medical options for ITP in pregnancy due to the teratogenicity of drugs and splenectomy is reserved for patient's refractory to medical management.

This report outlines a safe approach that may be implemented in cases where thrombocytopenia or associated complications mandate surgical intervention during pregnancy.

Case Presentation

A 33-year-old G2P1 female, in her 9th week of pregnancy, presented with oral mucosal bleeding and generalized petechiae over her limbs. Her past history was negative for bleeding or thrombocytopenia. Her platelet count (manual) was less than 10,000/ μ l and bone marrow biopsy revealed hypercellular marrow with increased megakaryocytes consistent with Immune Thrombocytopenia (ITP). Intravenous Methylprednisolone and Intravenous Immunoglobulin (IVIg) were administered at 0.5 g/kg daily (25 g) for 5 days. Her platelet count improved to 1,89,000/ μ l, following which she was discharged on oral steroids and azathioprine.

She presented a fortnight later with recurrent thrombocytopenia and generalized pustular eruptions. The platelet count was 7,000/ μ l and the wound culture was MRSA positive. Re-administration of intravenous steroids and IVIg increased the platelet count to 45,000/ μ l.

Ultrasound revealed a single live intrauterine fetus (weight- 112 g \pm 16 g) corresponding to 15 weeks. Spleen was mildly enlarged with no evidence of splenunculi.

Following a discussion with the patient and clinical team, plans were made to attempt laparoscopic splenectomy in the second trimester. Informed consent was obtained. Prophylactic vaccines for encapsulated bacteria and hepatitis B were administered. Six random donor platelet packs were infused before induction. Intravenous Ranitidine 50 mg and Metoclopramide 10 mg were administered at induction to prevent aspiration of gastric contents (Mendelson's syndrome).

The patient was placed in the right lateral position at 60 tilt with reverse Trendelenburg. Pneumoperitoneum was maintained at 12 mmHg. Hassan's cannula was used to place the primary 10 mm port on the left side 8 cm superolateral to the umbilicus. 10 mm, 5 mm and 5 mm ports were

OPEN ACCESS

*Correspondence:

Pinky M Thapar, Department of Minimal Invasive Surgery, Jupiter Hospital, Off Eastern Express Highway, Thane, Maharashtra 400 601, India, Tel: +91 9322222188;

E-mail: pinkythapar71@gmail.com

Received Date: 27 Dec 2022

Accepted Date: 09 Jan 2023

Published Date: 12 Jan 2023

Citation:

Thapar P, Lakshmanan A, Bhurat N, Shah S, Kamat A, Naik A, et al. Laparoscopic Splenectomy in Pregnancy – A Rescue Operation for Refractory Immune Thrombocytopenia: A Case Report. *World J Surg Surgical Res.* 2023; 6: 1441.

Copyright © 2023 Thapar P. This is an open access article distributed under the Creative Commons Attribution License, which permits unrestricted use, distribution, and reproduction in any medium, provided the original work is properly cited.

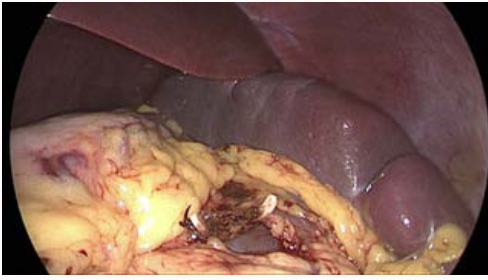


Figure 1: Ligated splenic artery with splenic vein.

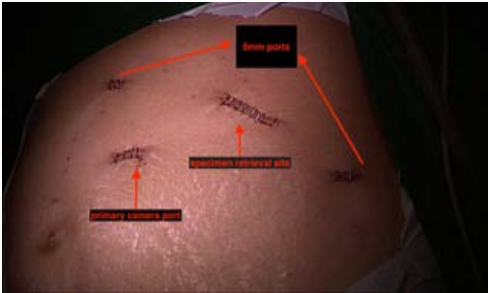

Figure 2: Port position.

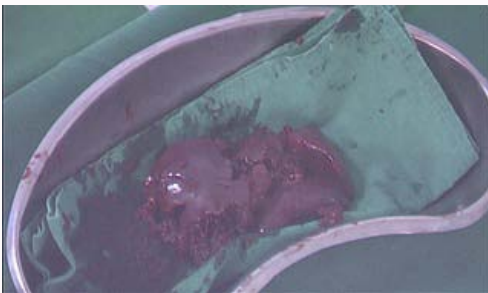


Figure 3: Piecemeal specimen of the spleen.

placed laparoscopically in the left midclavicular line, epigastrium, and the left lumbar anterior axillary line, respectively. Gastro splenic ligament was harmonized up to the superior pole of the spleen and the lesser sac was entered. The splenic artery was identified above the superior border of the pancreas, ligated and clipped (Figure 1).

The large polar artery was clipped and harmonized; dissection was done preserving the tail of the pancreas. The spleen was freed from its lateral, inferior, and posterior attachments. The splenic vein was dissected at the hilum, ligated, clipped, and cut. Piecemeal excision and retrieval of the spleen (weight- 205 g) were done through the primary 10 mm port (Figure 2, 3).

The histopathological report of the specimen suggested a congestive hemorrhagic enlarged spleen. Operative time was 120 min.

The postoperative course was uneventful. Duvadilan (Isoxsuprine) infusion followed by oral Duvadilan 10 mg thrice daily and progesterone 400 mg twice daily was administered to prevent preterm labor. Mechanical compression devices and stockings were used for thromboprophylaxis. She was discharged on the 4th postoperative day with a platelet count of 2,53,000/ μ l and normal fetal parameters. She subsequently had a normal delivery at 38 weeks' gestation. On a three-year follow-up, the patient is asymptomatic and

in complete remission.

Discussion

Since 1990, Laparoscopic Splenectomy (LS) has been performed with excellent results minimizing intraoperative and postoperative complications [2]. Today, laparoscopic splenectomy is considered safe and feasible with better outcomes compared to open splenectomy [3].

Immune Thrombocytopenia (ITP) in pregnancy is a complex situation with restricted medical options. According to the 2011 ASH guidelines, there are no studies comparing different treatment options in pregnant patients. First-line treatment for ITP includes corticosteroids, intravenous immunoglobulin, rituximab, and anti-D immunoglobulin. Cytotoxic and immunosuppressant drugs are best avoided in pregnancy, except azathioprine which is considered safe [4,5]. Patients who fail to respond to first-line treatment require an unacceptably high dose of steroids to maintain a safe platelet count which carries the risk of steroid-induced diabetes, infection, and fluid retention in the mother.

As per the ASH guidelines, the indications for splenectomy for ITP in pregnancy are refractory ITP or the presence of a hemorrhage with a platelet count of less than 10,000/ μ l [4-6]. LS during pregnancy was once considered a high-risk procedure for both mother and fetus due to potential complications such as abortion, preterm labor, and premature rupture of membranes [1,7]. These risks along with the risk of life-threatening hemorrhage due to severe thrombocytopenia have to be balanced with the benefits of laparoscopic splenectomy for the resolution of ITP. Though conventionally, the second trimester of pregnancy is considered best as the risk of anesthesia to the fetus is minimal and the uterine size does not complicate the procedure, a combined cesarian section with open splenectomy has also been reported, provided thrombocytopenia can be controlled till then with medical management [8].

Our patient could be managed by traditional measures only till early second trimester, when she presented with MRSA infection and a severe drop in platelet count to 7,000/ μ l. To safeguard maternal and fetal health during the relapse, the patient was offered a laparoscopic splenectomy in the second trimester. Preoperative optimization was done and adequate precautions were taken during anesthesia and surgery. The primary port was placed a little higher than normal and ultrasonic scissors were used for dissection. Mean arterial blood pressure was maintained in partial right lateral decubitus to ensure adequate fetal blood circulation. Vigilant monitoring of ETCO₂ was done. For specimen retrieval, Pfannenstiel incision was avoided to prevent uterine manipulation. Postoperatively, tocolytic agents were used to prevent preterm labor. Apart from the routine benefits of laparoscopy, other advantages of laparoscopy in pregnancy include decreased fetal respiratory depression due to diminished postoperative narcotic requirements, lower risk of wound complications, diminished postoperative maternal hypoventilation, and decreased risk of thromboembolic events [9]. LS has been sparsely reported in pregnancy for ITP, hairy cell leukemia and large splenic cyst [10,11].

Conclusion

Laparoscopic splenectomy provides a durable and long-term positive outcome in refractory ITP, thus making it a gold standard in rare scenarios. Clinicians should adopt a multidisciplinary approach

and weigh the risks and benefits of different treatment modalities when dealing with a clinical challenge with limited evidence.

Acknowledgment

We thank Jupiter Hospital for permitting us to use anonymized patient data for publication.

References

1. Mahey R, Kaur SD, Chumber S, Kriplani A, Bhatla N. Splenectomy during pregnancy: treatment of refractory immune thrombocytopenic purpura. *BMJ Case Rep.* 2013;2013:bcr2013201778.
2. Delaitre B. Laparoscopic splenectomy. *Surg Endosc.* 2001;15(10):1246.
3. Misiakos EP, Bagias G, Liakakos T, Machairas A. Laparoscopic splenectomy: Current concepts. *World J Gastrointest Endosc.* 2017;9(9):428-37.
4. Neunert C, Lim W, Crowther M, Cohen A, Solberg L Jr, Crowther MA; American Society of Hematology. The American Society of Hematology 2011 evidence-based practice guideline for immune thrombocytopenia. *Blood.* 2011;117(16):4190-4207.
5. Bernal-Macías S, Fino-Velásquez LM, Vargas-Barato FE, Guerra-Galve L, Reyes-Beltrán B, Rojas-Villarraga A. Refractory immunological thrombocytopenia purpura and splenectomy in pregnancy. *Case Rep Immunol.* 2015;2015:216362.
6. Neunert C, Terrell DR, Arnold DM, Buchanan G, Cines DB, Cooper N, et al. American Society of Hematology 2019 guidelines for immune thrombocytopenia. *Blood Adv.* 2019;3(23):3829-66.
7. Gottlieb P, Axelsson O, Bakos O. Splenectomy during pregnancy: An option in the treatment of autoimmune thrombocytopenic purpura. *BJOG* 1999;106:373-5.
8. Euliano TY, Zumberg MS, Frölich M. Cesarean section combined with splenectomy in a parturient with immune thrombocytopenic purpura. *J Clin Anesth.* 2001;13(4):313-8.
9. Pearl JP, Price RR, Tonkin AE. SAGES guidelines for the use of laparoscopy during pregnancy. *Surg Endosc.* 2017;31:3767-82.
10. Adeniji BA, Fallas M, Incerpi M, Hamburg S, Katz R, Ogunyemi D. Laparoscopic splenectomy for hairy cell leukemia in pregnancy. *Case Rep Med.* 2010;2010:136823.
11. Majesky I, Daniel I, Skultety J, Koudelka P, Hutan M. Laparoscopic splenectomy in pregnancy - from contraindication to golden standard. *Bratisl Lek Listy.* 2013;114:484-7.