



## Isolated Gall Bladder Tuberculosis Impersonating as Carcinoma Gall Bladder: A Case Report

Parvez Alam\*, Raza MH, Kafil Akhtar and Sameeksha Shah

Department of Surgery and Pathology, Jawaharlal Nehru Medical College and Hospital, Aligarh Muslim University, India

### Abstract

In India Tuberculosis (TB) is one of the common diseases affecting Indian population, where it contributes more than 25% to the global burden of this disease [1]. Isolated Gallbladder Tuberculosis (GT) is extremely rare entity owing to inhibitory action of bile to Mycobacterium tuberculosis. It is rarely diagnosed preoperatively due to its clinicoradiological similarity to other gallbladder disease such as Carcinoma Gallbladder (GC) and Xanthogranulomatous Cholecystitis (XGC). The final diagnosis is almost always made on the basis of surgical histopathological biopsy. In this, we detailed a case of patient who was admitted and underwent surgery with diagnosis of gallbladder carcinoma made before surgery.

**Keywords:** Isolated gallbladder tuberculosis; Carcinoma gall bladder; Frozen section; Chronic cholecystitis; XGC

### Introduction

Gallbladder tuberculosis is mostly infected with hematogenous tuberculosis or other intra-abdominal tuberculosis [2,3]. Very less case has been reported after the reporting of first case by Gaucher in 1870 [4]. It poses confusion during diagnosis in country like India where gall bladder carcinoma has high prevalence and Tuberculosis is endemic. It is very grueling to make diagnosis by clinical examination and imaging [5]. Diagnosis before surgery is seldom made but if made can avoid the unwanted radical surgery done for the suspicion of carcinoma. Here, we report a case of isolated GT operated with diagnosis of carcinoma GB based on CECT scan.

### OPEN ACCESS

#### \*Correspondence:

Parvez Alam, Department of Surgery and Pathology, Jawaharlal Nehru Medical College and Hospital, Aligarh Muslim University, Aligarh, UP 202002, India,

E-mail: parwez786amu@gmail.com

Received Date: 15 Mar 2021

Accepted Date: 07 Apr 2021

Published Date: 15 Apr 2021

#### Citation:

Alam P, Raza MH, Akhtar K, Shah S. Isolated Gall Bladder Tuberculosis Impersonating as Carcinoma Gall Bladder: A Case Report. World J Surg Surg Res. 2021; 4: 1302.

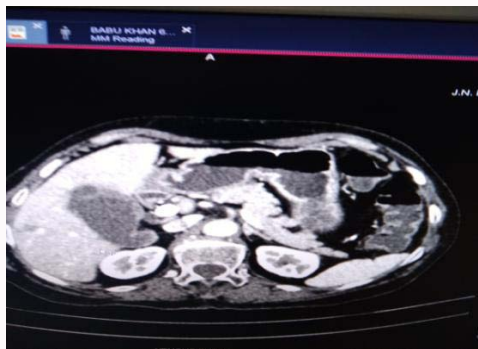Copyright © 2021 Parvez Alam. This is an open access article distributed under the Creative Commons Attribution License, which permits unrestricted use, distribution, and reproduction in any medium, provided the original work is properly cited.

### Case Presentation

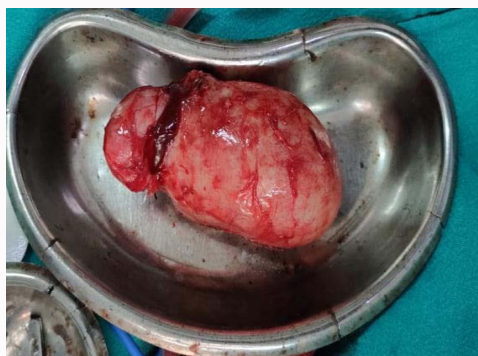We admitted a 60-year-old female patient for the complaints of recurrent pain in right hypochondrium and loss of appetite for past 4 months. No H/O constitutional symptoms like fever, weight loss, or night sweating, jaundice were present. No past h/o tuberculosis or any recent contact with pulmonary TB patients. Nothing significant found on general examination. On abdominal examination 5 cm × 5 cm firm, smooth globular lump was palpated in right hypochondrium moving with respiration. Laboratory investigations were normal. Chest X-ray was normal. On abdominal USG, distended gall bladder with gall stones an irregular thickening of GB wall was observed. Contrast-enhanced CT scan suggested 5 mm of focal thickening at fundus of gall bladder with maintained fat plane. A diagnosis of malignant GB thickening was made and open radical cholecystectomy was planned. Intraoperative, 11 cm × 5 cm × 3 cm of gallbladder was found with stone impacted at neck with thickening at fundus free from liver. The gallbladder was resected and sent for frozen-section examination which reported it to be favoring of chronic cholecystitis. The definitive histopathological examination of gallbladder was reported as gallbladder tuberculosis with moderate dysplasia. Microscopic examination shows epithelioid cells granulomas with Langhan's giant cells and widespread caseous necrosis and multilayering of columnar epithelium. And so patient was put onto antitubercular therapy and patient is recovering well.

### Discussion

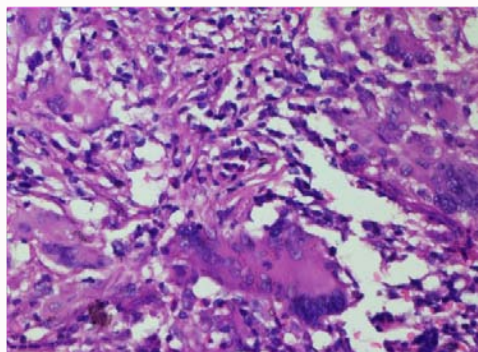
Gallbladder tuberculosis, particularly the isolated GT, is an uncommon disease entity [6]. GT is commonly associated with other intra abdomen tuberculosis, which *via* the lymphatic's or blood stream spreads to gall bladder, and GT mostly affects the women above the age of 30 [3,7]. Due to inhibitory action of bile gallbladder is resistant to tuberculosis. Gall bladder TB has occurred in association with miliary TB, disseminated abdominal TB, and isolated TB with immunodeficiency [8]. Cholelithiasis and cystic duct obstruction play important roles in pathology of GT [5]. GT



**Figure 1:** CT scan shows distended gall bladder with focal thickening at fundus of gall bladder with maintained interface.



**Figure 2:** Showing distended gallbladder with focal thickening at fundus.



**Figure 3:** Showing caseous necrosis with epithelioid cells granuloma.

patients may have wider range of complaints such as abdominal pain, icterus, and loss of weight, abdominal lump, and pain in right hypochondrium similar to other disease such as carcinoma GB. Around 70% of GT cases are associated with gallstones [9]. The unavailability of pathognomonic imaging paired with likelihood of high occurrence of tuberculosis in region endemic for carcinoma gall bladder makes preoperative diagnosis unlikely [10]. Due to overlapping clinical features a correct diagnosis is seldom made prior to surgery. We can detect elevated ESR and anemia, along with Mantoux tuberculin skin test. In gallbladder carcinoma, the frequent symptoms are pain (76%), weight loss (39%), jaundice (38%) and anorexia (32%) [11,12]. Serum CA19-9 can be evaluated to rule out carcinoma. CT scan showing intraluminal polypoid mass or invasion to adjacent organ or vessel can easily differentiate gallbladder carcinoma from other entity. In early stage carcinoma thickening can confuse the differential diagnosis. It was found that

infiltration into pericholecystic area, no break in mucosal line, gall stone, hypoattenuated nodule intramurally and diffuse thickening of GB wall were characteristics CT findings of XGC [13]. Enhanced gallbladder wall was more frequently seen in GC than XGC, and there is also difference in enhancement pattern among both [15]. In excessive suspicion, fine needle aspiration cytology can be done, but the likelihood of disease to be carcinoma should also be contemplated seriously [16]. Three different forms based on CT scan were shown for diagnosis of GT by Xu et al. [17]. On CT scan frequent morphological feature of GT wall is GB wall thickening which can be usually seen as GC or cholecystitis [18]. On CT scan halo can be observed in GT patients but not in patients of GC [19,20]. GT which shows mass on CT scan matches with that of GC having flecked type calcification of gallbladder wall [21]. The morphological features found on MRI of GT and GC was identical to one another as stated by Govindasamy et al. [22]. Antitubercular chemotherapy is the treatment of GT consists of two-month intensive periods of isoniazid (5 mg/kg), rifampicin (10 mg/kg), pyrazinamide (25 mg/kg to 30 mg/kg), and ethambutol (20 mg/kg), followed by continuation phase of four months of isoniazid and rifampicin [23].

## Conclusion

There are no pathognomonic clinical features or any specific investigation to correctly diagnose GB tuberculosis preoperatively posing diagnostic dilemma in an endemic county like India. But combination of CT with clinical symptoms and laboratory investigations might be used to approach GT. Intraoperative frozen section is helpful to rule out malignancy and avoid radical surgery in this group of patients. Ultimately the diagnosis is confirmed on the basis of histopathological analysis of resected specimen by pathologist.

## References

1. World Health Organization. Global Tuberculosis Report 2017. Geneva: World Health Organization, 2017.
2. Chen CH, Yang CC, Yeh YH, Yang JC, Chou DA. Pancreatic tuberculosis with obstructive jaundice--a case report. *Am J Gastroenterol.* 1999;94(9):2534-6.
3. Collier NA, Blumgart LH. "Tumours of gall bladder," in *Surgery of the Liver and Biliary Tract.* Blumgart LH, editor. Churchill Livingstone, New York, NY, USA, 2<sup>nd</sup> edition. 1994. p. 55-6.
4. Bergdahl L, Boquist L. Tuberculosis of the gall-bladder. *Br J Surg.* 1972;59(4):289-92.
5. Jain R, Sawhney S, Bhargava D, Berry M. Gallbladder tuberculosis: Sonographic appearance. *J Clin Ultrasound.* 1995;23(5):327-9.
6. Rejab H, Guirat A, Ellouze S, Trigui A, Mizouni A, Triki H, et al. Primitive gallbladder tuberculosis: A case report with review of the literature. *Ann Ital Chir.* 2013;84(ePub):1-3.
7. Abu-Zidan FM, Zayat I. Gallbladder tuberculosis (Case report and review of the literature). *Hepatogastroenterology.* 1999;46(29):2804-6.
8. Gupta A, Anjum R, Agrawal S, Mallik D, Amit G. A comprehensive review on primary gallbladder tuberculosis. *Pol Przegl Chir.* 2018;90(2):10-2.
9. Yu R, Liu Y. Gallbladder tuberculosis: Case report. *Chin Med J.* 2002;115(8):1259-61.
10. Liy Y, Wang K, Liu H. Gall bladder tuberculosis mimicking gallbladder carcinoma: A case report and literature review. *Case Reports Hepatol.* 2016;3629708.
11. Xin-Wei Y, Jue Y, Bao-Hua Z, Feng S. An unusual gallbladder carcinoma

- with tumor thrombus in the common bile duct. *J Cancer Res Ther.* 2013;9(1):122-4.
12. Kayahara M, Nagakawa T. Recent trends of gallbladder cancer in Japan: An analysis of 4770 patients. *Cancer.* 2007;110(3):572-80.
13. Goshima S, Chang S, Wang JH, Kanematsu M, Bae KT, Federle MP. Xanthogranulomatous cholecystitis: Diagnostic performance of CT to differentiate from gallbladder cancer. *Euro J Radiol.* 2010;74(3):e79-83.
14. Kim SJ, Lee JM, Lee JY. Analysis of enhancement pattern of flat gallbladder wall thickening on MDCT to differentiate gallbladder cancer from cholecystitis. *Am J Roentgenol.* 2008;191(3):765-71.
15. Goh V, Halligan S, Taylor SA, Burling D, Bassett P, Bartram CI. Differentiation between diverticulitis and colorectal cancer: Quantitative CT perfusion measurements versus morphologic criteria—initial experience. *Radiology.* 2007;242(2):456-62.
16. Rana C, Krishnani N, Kumari N. Ultrasound-guided fin needle aspiration cytology of gall bladder lesion: A study of 596 cases. *Cytopathology.* 2016;27(6):398-406.
17. Xu XF, Yu RS, Qiu LL, Shen J, Dong F, Chen Y. Gallbladder tuberculosis: CT findings with histopathologic correlation. *Korean J Radiol.* 2011;12(2):196-202.
18. Saluja SS, Ray S, Pal S, Kukeraja M, Srivastava DN, Sahni P, et al. Hepatobiliary and pancreatic tuberculosis: A two decade experience. *BMC Surg.* 2007;7(10).
19. Banerjee S, Sen S. Tuberculosis of the gall bladder. *J Indian Med Assoc.* 2003;101(9):556-7.
20. Ruhl KM, Krones CJ, Hermanns B, Schumpelick V. Tuberculosis of the gall bladder. *Chirurg.* 2003;74(5):478-81.
21. Ben RJ, Young T, Lee HS. Hepatobiliary tuberculosis presenting as a gall bladder tumor. *Scand J Infect Dis.* 1995;27(4):415-7.
22. Govindasamy M, Srinivasan T, Varma V, Mehta N, Yadav A, Kumaran V, et al. Biliary tract tuberculosis - a diagnostic dilemma. *J Gastrointest Surg.* 2011;15(12):2172-7.
23. Malki HO, Benkabbou A, Mohsine R, Ifrine L, Belkouchi A, Balafrej S. Gallbladder tuberculosis (Article in French). *Can J Surg.* 2006;49(2):135-6.