World Journal of Surgery and Surgical Research

Research Article
Published: 28 Mar, 2020

Incidence and Prognosis of Duodenal Stump Leakage in Laparoscopic Gastrectomy for Gastric Cancer According to Treating Duodenal Stump

*Min Chan Kim**

Department of Surgery, Dong-A University College of Medicine, Korea

Abstract

Background: Duodenal Stump Leakage (DSL) can be a feared and life-threatening complication after gastrectomy. DSL after laparoscopic surgery can be a bigger disappointment than that after open surgery.

Aim: To compare surgical outcomes according to three surgical techniques to treat duodenal stump in laparoscopic gastrectomy and establish the best surgical technique to prevent duodenal stump leakage in laparoscopic gastrectomy for gastric cancer.

Materials and Methods: A total of 762 patients who underwent laparoscopic gastrectomy for gastric cancer between April 2003 and March 2017 were enrolled. They were divided into three groups based on surgical technique used to treat duodenal stump: Only glue group (group G), Polyglycolic Acid (PGA) sheet and glue group (group P+G), and laparoscopic reinforcement suture with Polyglycolic Acid (PGA) sheet and glue group (group R+P+G). Clinicopathologic characteristics and surgical outcomes were compared among three groups retrospectively.

Results: Overall incidence of DSL after laparoscopic gastrectomy for gastric cancer was 1.0% (8/762). Among them, four patients with major DSL unfortunately died after reoperation. There are no significant differences in surgical outcomes among the three groups, except operation time. The operation time was the shortest in the R+P+G group. Incidences of DSL in G group and P+G group were 2.1% and 1.1 %, respectively. However, there was no DSL in the R+P+G group.

Conclusion: Application of Polyglycolic Acid (PGA) sheet and fibrin glue on laparoscopic reinforcement suture site for stapler line of duodenal stump can be one of prevention methods for DSL after laparoscopic gastrectomy for gastric cancer.

Keywords: Laparoscopy; Gastrectomy; Postoperative complication; Duodenum

OPEN ACCESS

Correspondence:
Min Chan Kim, Department of Surgery, Dong-A University College of Medicine, 26 Daesingongwon-Ro, Seo-Gu, Busan, 49201, Korea, Tel: 82-51-240-5146; Fax: 82-51-247-9316; E-mail: mckim@dau.ac.kr

Received Date: *16 Feb 2020*
Accepted Date*: 25 Mar 2020*
Published Date*: 28 Mar 2020*

Citation:
Kim MC. Incidence and Prognosis of Duodenal Stump Leakage in Laparoscopic Gastrectomy for Gastric Cancer According to Treating Duodenal Stump. World J Surg Surgical Res. 2020; 3: 1211.

Introduction

Duodenal Stump Leakage (DSL) can be a feared and life-threatening complication after gastrectomy. The incidence of duodenal stump leakage is reportedly between 1.6% to 5% in Billroth II or Roux-en-Y reconstruction after gastrectomy for gastric cancer [1]. Minor duodenal stump leakage is well managed by conservative treatment. However, unstable patient with major duodenal stump leakage unfortunately may not be recoverable by medical or surgical treatment [2,3]. Especially, DSL after laparoscopic surgery can be a bigger disappointment than that after open surgery in terms of patient's surgical satisfaction.

Recently, laparoscopic gastrectomy has been adopted as a curative treatment for gastric cancer in Eastern Asian countries. Three multicenter randomized controlled trials (KLASS-01 [4], CLASS 01 [5], JCOG0703 [6]) of laparoscopic distal gastrectomy for gastric cancer have shown favorable results compared to open gastrectomy. However, DSL remains one of important issues of laparoscopic gastrectomy for gastric cancer. There are few data of DSL after laparoscopic gastrectomy for gastric cancer. The best surgical technique for prevention of DSL in laparoscopic gastrectomy is not established yet.

Therefore, the objective of this study aims to compare surgical outcomes according to three surgical techniques used to treat duodenal stump in laparoscopic gastrectomy and establish the best surgical technique for preventing DSL in laparoscopic gastrectomy for gastric cancer.

Materials and Methods

This was a retrospective study using prospective collected database. Between April 2003 and March 2017, a total of 762 patients who underwent laparoscopic distal gastrectomy with B-II or Roux-en-Y gastrojejunostomy or laparoscopic total gastrectomy with Roux-en-Y esophagojejunostomy for gastric cancer (performed by MC Kim) at Dong-A University Hospital were enrolled. Our indication for laparoscopic distal gastrectomy for gastric cancer was extended from clinical T1N0M0 at 2002 to less than clinical T3N1M0 without bulky tumor or conglomerated metastatic lymph node at 2014.

In our institute, the surgical technique used to treat duodenal stump in laparoscopic gastrectomy for gastric cancer has changed as time passes. For the first group (group G), only fibrin glue was applied on stapler line of duodenal stump after cutting the duodenum using linear stapler from April 2003 to April 2011. For the second group (group P+G), Polyglycolic Acid (PGA) sheet and fibrin glue were applied from May 2011 to June 2015. For the third group (group R+P+G), Polyglycolic Acid (PGA) sheet and fibrin glue were applied on laparoscopic reinforcement suture site for stapler line of duodenal stump from July 2015 to March 2017 (Figure 1). Detailed technique of laparoscopic reinforcement suture has been reported previously [7,8].

Fluorescence images after 1 minute of Indocyanine Green (ICG) intravenous injection were taken for blood perfusion of duodenal stump before and after laparoscopic reinforcement suture.

Clinicopathologic characteristics such as age, gender, body mass index, presence of co-morbidity, number of co-morbidity, and pathologic TNM stage and surgical outcomes such as incidence of DSL, operation time, extent of gastric resection, type of reconstruction, combined surgery, intra or postoperative transfusion, postoperative hospital stay, postoperative complication, and Clavien-Dindo (C-D) classification of complication were compared among the three groups. Detailed data of 8 patients with duodenal stump leakage were investigated.

We defined DSL by the presence of biliary-enteric drainage which would exist through the abdominal wall confirmed by abdominal-pelvic CT scan or fistulography. Image studies were performed in patients who presented symptoms and signs such as severe and abrupt abdominal pain, fever, worsening leukocytosis, and clinical suspicion of DSL [7]. Minor DSL was defined as the presence of biliary-enteric drainage without some symptoms of peritonitis. On the other hand, major DSL was defined as the presence of biliary-enteric drainage with some symptoms of peritonitis.

This study was performed under approval of the Institutional Review Board at Dong-A University Hospital (IRB No. DAUHIRB-17-100). The requirement for informed consent from patients was waived due to its retrospective nature.

Results

Overall incidence of DSL after laparoscopic gastrectomy for gastric cancer was 1.0% (8/762).

Fluorescence images of duodenal stumps before and after laparoscopic reinforcement suture

After laparoscopic reinforcement suture with invagination on stapler line of duodenal stump, a dark ischemic stapler line disappeared on fluorescence image using Indocyanine Green (ICG) (Figure 2).

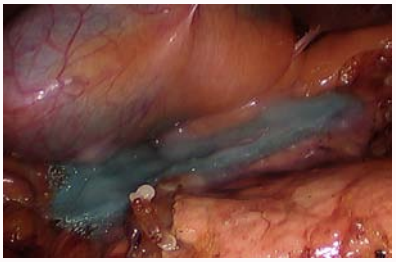

Figure 1: In the R+P+G group, Polyglycolic Acid (PGA) sheet and fibrin glue were applied on laparoscopic reinforcement suture site for stapler line of duodenal stump.

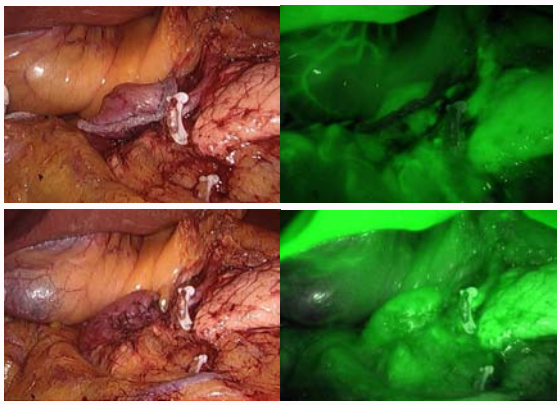

Figure 2: Simple laparoscopic (A and C) and fluorescence image (B and D) views of duodenal stump before and after laparoscopic reinforcement suture. After laparoscopic reinforcement suture with invagination on stapler line of duodenal stump, a dark ischemic stapler line disappeared on fluorescence image using Indocyanine Green (ICG) (D).

Clinicopathologic characteristics among three groups according to technique used to treat duodenal stump

There were significant differences in clinical characteristics, such as age, presence of co-morbidity and number of co-morbidity among the three groups. In the R+P+G group, patients had the oldest age with the highest presence of co-morbidity and the highest number of co-morbidity. However, these differences were not affected by the three groups themselves, but time lag (Table 1).

Surgical outcomes among three groups according to technique used to treat duodenal stump

Incidences of DSL in G group and P+G group were 2.1% and 1.1%, respectively. However, there was no major and minor DSL in the R+P+G group. Minor DSL did not occur in the R+P+G group or the P+G group. There are no significant differences in surgical outcomes among the three groups, except operation time. The operation time for the R+P+G group was the shortest among the three groups although additional laparoscopic reinforcement suture was needed. However, this difference was mainly due to the most recent R+P+G technique (Table 2).

Development, treatment, and results of eight patients having duodenal stump leakage

The interval between the first operation and DSL date was longer in the P+G group than that in the G group, although the difference was not statistically significant. In the G group, four (2.1%, 4/191) patients had duodenal stump leakage. One minor DSL of these four

Table 1: Clinicopathologic characteristics among three groups according to technique used to treat duodenal stump.

	Group G (n=191)	Group P + G (n=382)	Group R + P + G (n=189)	*P* value
Age (mean ± SD)	57.9 ± 12.7	60.5 ± 11.3	63.5 ± 10.9	0
Gender				0.75
Male	127 (66.5%)	244 (63.9%)	119 (63.0%)	
Female	64 (33.5%)	138 (36.1%)	70 (37.0%)	
Body mass index (mean ± SD, kg/m^2)	23.6 ± 3.3	23.7 ± 2.9	23.9 ± 3.4	0.524
Co-morbidity (%)	68 (35.6%)	166 (43.5%)	122 (64.6%)	0
Number of co-morbidity				0
none	123 (64.4%)	216 (56.5%)	67 (35.4%)	
01-3	44 (23.0%)	118 (30.9%)	65 (34.4%)	
>4	24 (12.6%)	48 (12.6%)	57 (30.2%)	
Pathologic TNM stage				0.094
0	2 (1.0%)	6 (1.6%)	0 (0.0%)	
I	148 (77.5%)	314 (82.2%)	160 (84.7%)	
II	24 (12.6%)	48 (12.6%)	20 (10.6%)	
III	17 (8.9%)	14 (3.7%)	9 (4.8%)	

G: Glue; P + G: Polyglycolic Acid (PGA) + Glue; R + P + G: Laparoscopic Reinforcement Suture + Polyglycolic Acid (PGA) + Glue; SD: Standard Deviation

Table 2: Surgical outcomes among three groups according to technique used to treat duodenal stump.

	Group G (n=191)	Group P + G (n=382)	Group R + P + G (n=189)	*P* value
Duodenal stump leakage (%)	4 (2.1%)	4 (1.1%)	0 (%)	0.139
Operation time (min, mean ± SD)	214.8 ± 52.5	162.5 ± 40.5	145.7 ± 28.3	0
Extent of gastric resection				0.545
Total	49 (25.7%)	32 (8.4%)	21 (11.1%)	
Distal	142 (74.3%)	350 (91.6%)	168 (88.9%)	
Type of reconstruction				0.613
B-II	139 (72.8%)	334 (87.4%)	167 (88.4%)	
Roux en Y EJ	52 (27.2%)	38 (9.9%)	21 (11.1%)	
Roux en Y GJ	0 (0.0%)	0 (0.0%)	1 (0.5%)	
Uncut Roux en Y GJ	0 (0.0%)	10 (2.6%)	0 (0.0%)	
Combined surgery (%)	9 (4.7%)	26 (6.8%)	13 (6.9%)	0.58
Intra or postoperative transfusion (%)	8 (4.2%)	9 (2.4%)	5 (2.6%)	0.454
Postoperative hospital stay (day, mean ± SD)	8.6 ± 10.2	8.2 ± 4.3	8.0 ± 5.1	0.667
Postoperative complication (%)	20 (10.5%)	63 (16.5%)	20 (10.6%)	0.055
C-D classification of complication				0.234
I-II	12 (6.3%)	49 (12.8%)	16 (8.5%)	
≥ III	8 (4.2%)	14 (3.7%)	4 (2.1%)	

G: Glue; P + G: Polyglycolic Acid (PGA) + Glue; R + P + G: Laparoscopic Reinforcement Suture + Polyglycolic Acid (PGA) + Glue; SD: Standard Deviation; B-II: Bilroth II; EJ: Esophag Jejunostomy; GJ: Gastrojejunostomy; C-D: Clavien-Dindo

duodenal stump leakage patients was recovered by only conservative treatment. One patient died of respiratory failure in the G group. In the P+G group, four (1.1%, 4/382) patients had major duodenal stump leakage. Unfortunately, three of these four patients died, including two patients died of sepsis and one patient died of hepatic failure (Table 3).

Clinicopathologic characteristics of 8 patients with duodenal stump leakage

Seven of eight duodenal stump leakage patients were male. All patients underwent partial omentectomy. There is no secondary leakage affected by pancreatitis, afferent loop syndrome and small bowel obstruction. Except one patient, all duodenal stump leakages developed less than postoperative 5 days. Causes of four deaths were one respiratory failure, one liver failure, and two sepses (Table 4).

Discussion

Radical gastrectomy with D2 lymph node dissection for gastric cancer remains a challenging surgery with a high morbidity rate in the West. Morbidity and mortality rates in two western Randomized Controlled Trials (RCT) [9,10] were 25% to 46% and 4% to 13%, respectively. In laparoscopic gastrectomy, three prospective randomized multicenter trials [4-6] in the East have demonstrated a morbidity rate of 13.7% to 16.4% and a mortality rate of 0% to 0.6%.

Table 3: Development, treatment, and results of eight patients having duodenal stump leakage.

	Group G (n=191)	Group P + G (n=382)	*P* value
Duodenal stump leakage (%)	4 (2.1%)	4 (1.1%)	0.314
Interval between first operation and DSL date (day, mean ± SD)	2.75 ± 1.71	5.50 ± 2.52	0.121
Treatment of DSL			0.985
Conservative	1 (0.5%)	0 (0.0%)	
Reoperation	3 (1.6%)	4 (1.0%)	
Mortality	1 (0.5%)	3 (0.8%)	0.723
Cause of mortality			0.527
Sepsis	0 (0.0%)	2 (0.5%)	
Respiratory failure	1 (0.5%)	0 (0.0%)	
Hepatic failure	0 (0.0%)	1 (0.3%)	

G: Glue; P + G: Polyglycolic Acid (PGA) + Glue; SD: Standard Deviation; DSL: Duodenal Stump Leakage

Table 4: Clinicopathologic characteristics of 8 patients with duodenal stump leakage.

No.	Gender	Age	BMI (kg/m^2)	Co-morbidity	Extent of gastric resection	Reconstruction	Combined surgery	Operation time (min.)	p TNM stage	Transfusion (pint)	Interval between first operation and DSL date (day)	Reoperation or not	HS	Mortality, cause of death
1	Male	60	23.7	None	Distal	B-II	None	260	IIb	None	3	Reoperation	121	No
2	Male	68	28	DM	Total	Roux en Y EJ	None	290	Ia	None	1	Reoperation	15	No
3	Male	64	28.1	None	Distal	B-II	Cholecystectomy	315	Ia	None	2	Conservative	12	No
4	Male	74	19	HT,CAD, DM	Distal	B-II	None	170	Ia	9	5	Reoperation	21	Yes, resp. failure
5	Male	59	26.2	None	Distal	B-II	None	190	Ia	None	9	Reoperation	15	No
6	Male	53	23.4	Hepatitis	Distal	B-II	None	180	Ib	None	3	Reoperation	7	Yes, sepsis
7	Male	67	28	COPD	Distal	B-II	None	145	Ia	None	5	Reoperation	8	Yes, sepsis
8	Female	74	24.9	HT, RA	Distal	B-II	None	115	Ia	None	5	Reoperation	45	Yes, liver failure

BMI: Body Mass Index; DSL: Duodenal Stump Leakage; HS: Hospital Stay; B-II: Bilroth II; DM: Diabetes Mellitus; EJ: Esophag Jejunostomy; HT: Hypertension; CAD: Coronary Artery Disease; COPD: Chronic Obstructive Pulmonary Disease; RA: Rheumatoid Arthritis

A population-based cohort study [11] of laparoscopic gastrectomy in the West reported a morbidity rate of 37% and a mortality rate of 6%. These differences in surgical outcomes between the East and the West are most likely due to differences in patients' characteristics and tumor biology as well as the incidence and stage of gastric cancer [12,13]. In spite of many specialized high volume centers in the East, anastomotic leakage after laparoscopic gastrectomy for gastric cancer still remains one of big issues [14,15]. Among these anastomotic leakages after laparoscopic gastrectomy, duodenal stump leakage can be the most serious complication because of impending sepsis or death despite reoperation for major duodenal stump leakage. Overall anastomotic leakage after laparoscopic gastrectomy for gastric cancer reportedly occurred in 1% to 2% of patients in several large-scale studies [14,15]. However, there is little information about the exact incidence of duodenal stump leakage or effective closure of duodenal stump in laparoscopic gastrectomy for gastric cancer.

In our previous study [16] about duodenal stump leakage after open or laparoscopic gastrectomy for gastric cancer, 13 (1.1%) among 1,195 patients suffered from duodenal stump leakage. Age was the only risk factor associated with duodenal stump leakage. Initially, this study planned to perform analysis to identify risk factors associated with duodenal stump leakage after 762 laparoscopic gastrectomies. However, statistical analysis could not be performed due to too small number of events. Therefore, clinicopathologic characteristics and surgical outcomes were compared among the three groups according to techniques used to treat duodenal stump sequentially.

Duodenal stump leakage can be affected by patient and surgeon factors [1,17,18]. Patient factors include age, co-morbidity, preoperative nutritional status, chronic ulcer or ectopic pancreas, cancer invasion to pylorus, and gastric outlet obstruction. Surgeon factors include excessive vascular or pancreatic dissection around duodenal stump or direct thermal injury by ultrasonic shears. According to a review article about surgical treatment for anastomotic leakage after upper gastrointestinal surgery, early leakage (<72 h after initial operation) is usually being interpreted as a technical error [19].

Treatment of DSL includes conservative, endoscopic, and surgical management. Minor duodenal stump leakage is well managed by only conservative treatment. Adequate drain of biliary-enteric fluid and control of infection are mandatory for treatment of major DSL [1]. A pigtail or Foley catheter can be used and the establishment of a controlled fistula is an available treatment option [20]. Surgical management of major DSL can be recommended in case of sepsis with one or multi-organ failures, presence of signs of diffuse peritonitis, or inefficient drainage through a radiological or endoscopic approach. Therefore, surgical management of DSL has high postoperative mortality [19]. Recently, an interesting technique as endoscopic clipping with or without Polyglycolic Acid (PGA) sheet for treatment of DSL has been introduced [21].

The Polyglycolic Acid (PGA) sheet can be hydrolyzed easily in conditioned circumstance. It is usually absorbed in three months [22]. In addition, because the absorption rate of water is high in the

PGA sheet, the fibrin glue is considered to be attached strongly to the cut surface of the organ using PGA sheet [23] Bioabsorbable Polyglycolic Acid (PGA) sheet with fibrin glue has been used to prevent leakage from some cut surface in various surgeries such as preventing pancreatic fistula in pancreatic surgery [24], bile leakage in liver surgery [23], air leakage in video-assisted major pulmonary resection [25], and Cerebrospinal Fluid (CSF) leakage in spinal surgery [26].

Reinforcement suture on stapler line of duodenal stump is a traditional and wide-spread technique for preventing DSL in open gastrectomy. This technique has been introduced to laparoscopic surgery in our institute since 2015. Retrospective [7] and prospective studies [8] of laparoscopic reinforcement suture on stapler line of duodenal stump have been conducted in our institute. Similar technique of laparoscopic gastrectomy has been reported by a retrospective study in Japan [27]. Reinforcement suture of stapler line can prevent duodenal stump leakage due to enhancement of blood supply of duodenal tissue based on fluorescence image. In open radical gastrectomy for gastric cancer, duodenal stump closure using purse-string suture without stapling has been introduced as a promising approach with shorter operative time and lower cost and incidence of duodenal stump leakage [28].

There are some limitations in this study. Three methods was performed during different period, thereby there seems many confounding factors which might affect the results. The surgeon's experience or advances in laparoscopic instruments might affect the rate of duodenal stump leakage. Other limitations of this study are inherent due to the lack of randomization among the three groups and proof of positive effect of this unique technique (group R+P+G). A prospective randomized controlled trial is needed to confirm the superiority of this technique. However, this is practically difficult because too many patients are required.

In summary, this study revealed that incidences of DSL according to three different techniques used to treat duodenal stump was 2.1% in the G group, 1.1% in the P+G group, and 0% in the R+P+G group. Overall incidence of DSL after laparoscopic gastrectomy for gastric cancer was 1.0% (8/762). Among them, four patients with major DSL unfortunately died after reoperation. Application of Polyglycolic Acid (PGA) sheet and fibrin glue after laparoscopic reinforcement suture on stapler line of the duodenum can be one of prevention methods for DSL after laparoscopic gastrectomy for gastric cancer.

References

1. Aurello P, Sirimarco D, Magistri P, Petrucciani N, Berardi G, Amato S, et al. Management of duodenal stump fistula after gastrectomy for gastric cancer: Systematic review. World J Gastroenterol. 2015;21(24):7571-6.
2. Cozzaglio L, Giovenzana M, Biffi R, Cobianchi L, Coniglio A, Framarini M, et al. Surgical management of duodenal stump fistula after elective gastrectomy for malignancy: An Italian retrospective multicenter study. Gastric Cancer. 2016;19(1):273-9.
3. Paik HJ, Lee SH, Choi CI, Kim DH, Jeon TY, Kim DH, et al. Duodenal stump fistula after gastrectomy for gastric cancer: risk factors, prevention, and management. Ann Surg Treat Res. 2016;90(3):157-63.
4. Kim W, Kim HH, Han SU, Kim MC, Hyung WJ, Ryu SW, et al. Decreased morbidity of laparoscopic distal gastrectomy compared with open distal gastrectomy for stage I gastric cancer: Short-term outcomes from a multicenter randomized controlled trial (KLASS-01). Ann Surg. 2016;263(1):28-35.
5. Hu Y, Huang C, Sun Y, Su X, Cao H, Hu J, et al. Morbidity and mortality of laparoscopic versus open D2 distal gastrectomy for advanced gastric cancer: A randomized controlled trial. J Clin Oncol. 2016;34(12):1350-7.
6. Hiki N, Katai H, Mizusawa J, Nakamura K, Nakamori M, Yoshikawa T, et al. Long-term outcomes of laparoscopy-assisted distal gastrectomy with suprapancreatic nodal dissection for clinical stage I gastric cancer: A multicenter phase II trial (JCOG0703). Gastric Cancer. 2018;21(1):155-61.
7. Kim SY, Nam SH, Min JS, Kim MC. Laparoscopic reinforcement suture on staple-line of duodenal stump using barbed suture during laparoscopic gastrectomy for gastric cancer. Ann Surg Treat Res. 2017;93(6):305-9.
8. Kim MC, Kim SY, Kim KW. Laparoscopic Reinforcement Suture (LARS) on staple line of duodenal stump using barbed suture in laparoscopic gastrectomy for gastric cancer: A prospective single arm phase II study. J Gastric Cancer. 2017;17(4):354-62.
9. Bonenkamp JJ, Hermans J, Sasako M, van de Velde CJ, Welvaart K, Songun I, et al. Extended lymph-node dissection for gastric cancer. N Engl J Med. 1999;340(12):908-14.
10. Cuschieri A, Weeden S, Fielding J, Bancewicz J, Craven J, Joypaul V, et al. Patient survival after D1 and D2 resections for gastric cancer: Long-term results of the MRC randomized surgical trial. Surgical Co-operative Group. Br J Cancer. 1999;79(9-10):1522-30.
11. Brenkman HJF, Gisbertz SS, Slaman AE, Goense L, Ruurda JP, van Berge Henegouwen MI, et al. Postoperative outcomes of minimally invasive gastrectomy versus open gastrectomy during the early introduction of minimally invasive gastrectomy in the Netherlands: A population-based cohort study. Ann Surg. 2017;266(5):831-8.
12. Shim JH, Song KY, Jeon HM, Park CH, Jacks LM, Gonen M, et al. Is gastric cancer different in Korea and the United States? Impact of tumor location on prognosis. Ann Surg Oncol. 2014;21(7):2332-9.
13. Russo A, Li P, Strong VE. Differences in the multimodal treatment of gastric cancer: East versus west. J Surg Oncol. 2017;115(5):603-14.
14. Kitano S, Shiraishi N, Uyama I, Sugihara K, Tanigawa N; Japanese Laparoscopic Surgery Study Group. A multicenter study on oncologic outcome of laparoscopic gastrectomy for early cancer in Japan. Ann Surg. 2007;245(1):68-72.
15. Kim MC, Kim W, Kim HH, Ryu SW, Ryu SY, Song KY, et al. Risk factors associated with complication following laparoscopy-assisted gastrectomy for gastric cancer: a large-scale Korean multicenter study. Ann Surg Oncol. 2008;15(10):2692-700.
16. Kim KH, Kim MC, Jung GJ. Risk factors for duodenal stump leakage after gastrectomy for gastric cancer and management technique of stump leakage. Hepatogastroenterology. 2014;61(133):1446-53.
17. Cornejo Mde L, Priego P, Ramos D, Coll M, Ballestero A, Galindo J, et al. Duodenal fistula after gastrectomy: Retrospective study of 13 new cases. Rev Esp Enferm Dig. 2016;108(1):20-6.
18. Orsenigo E, Bissolati M, Socci C, Chiari D, Muffatti F, Nifosi J, et al. Duodenal stump fistula after gastric surgery for malignancies: a retrospective analysis of risk factors in a single centre experience. Gastric Cancer. 2014;17(4):733-44.
19. Hummel R, Bausch D. Anastomotic Leakage after Upper Gastrointestinal Surgery: Surgical Treatment. Visc Med. 2017;33(3):207-11.
20. Ali BI, Park CH, Song KY. Outcomes of non-operative treatment for duodenal stump leakage after gastrectomy in patients with gastric cancer. J Gastric Cancer. 2016;16(1):28-33.
21. Han S, Chung H, Park JC, Shin SK, Lee SK, Lee YC. Endoscopic management of gastrointestinal leaks and perforation with polyglycolic acid sheets. Clin Endosc. 2017;50(3):293-6.
22. Nakamura T, Shimizu Y, Watanabe S, Hitomi S, Kitano M, Tamada J, et al. New bioabsorbable pledgets and non-woven fabrics made from polyglycolide (PGA) for pulmonary surgery: Clinical experience. Thorac

Cardiovasc Surg. 1990;38(2):81-5.

23. Hayashibe A, Sakamoto K, Shinbo M, Makimoto S, Nakamoto T. New method for prevention of bile leakage after hepatic resection. J Surg Oncol. 2006;94(1):57-60.

24. Ochiai T, Sonoyama T, Soga K, Inoue K, Ikoma H, Shiozaki A, et al. Application of polyethylene glycolic acid felt with fibrin sealant to prevent postoperative pancreatic fistula in pancreatic surgery. J Gastrointest Surg. 2010;14(5):884-90.

25. Ueda K, Tanaka T, Jinbo M, Yagi T, Li TS, Hamano K. Sutureless pneumostasis using polyglycolic acid mesh as artificial pleura during video-assisted major pulmonary resection. Ann Thorac Surg. 2007;84(6):1858-61.

26. Hida K, Yamaguchi S, Seki T, Yano S, Akino M, Terasaka S, et al. Nonsuture dural repair using polyglycolic acid mesh and fibrin glue: Clinical application to spinal surgery. Surg Neurol. 2006;65(2):136-42.

27. Inoue K, Michiura T, Fukui J, Mukaide H, Ozaki T, Miki H, et al. Staple-line reinforcement of the duodenal stump with intracorporeal lembert's sutures in laparoscopic distal gastrectomy with roux-en-y reconstruction for gastric cancer. Surg Laparosc Endosc Percutan Tech. 2016;26(4):338-42.

28. Shao QS, Wang YX, Ye ZY, Zhao ZK, Xu J. Application of purse-string suture for management of duodenal stump in radical gastrectomy. Chin Med J (Engl). 2011;124(7):1018-21.