



Extended High Hilar Resection and Enlarged Hepatic Portal Enterostomy in the Treatment of Hilar Cholangiocarcinoma

Abdul Qahar Saleh*, Chen Yu-Xin, Ning Shang Lei, Guo Ling Yu and Habibullah Fitrat

Department of Hepatobiliary, Qilu Hospital of Shandong University, China

Abstract

Background: Tertiary biliary radical reconstruction and biliary-enteric continuity restoration limits the radical resection of hilar cholangiocarcinoma, because there are multiple biliary radicals in the cut surface of liver and some of them are smaller than 1 mm to 2 mm. Enlarged anastomosis orifice might delay the jaundice related to local recurrence which is the main cause of long-term morbidity and mortality. We proposed extended high hilar resection and enlarged hepatic portal parenchyma-enterostomy for hilar cholangiocarcinoma.

Methods: Fifty-six patients of hepatic hilar cholangiocarcinoma were referred for surgical treatment from March 2016 to March 2018. Duplex Ultrasonography (US), Computed Tomography (CT) and/or Magnetic Resonance Cholangiopancreatography (MRCP) were applied to evaluate the range of invasion and distant metastasis of tumors. Percutaneous Transhepatic Biliary Drainage (PTCD) and bile refusion were performed on patients with Child Grade C, and a Total Bilirubin (TB) level higher than 400 $\mu\text{mol/L}$ and Child Grade B or above.

Results: Hepatic hilar resection and portal parenchyma-enterostomy was performed on 51 patients, and stent enterostomy was carried out on 5 patients. Eleven patients underwent right hepatic artery resection and partial resection of portal vein was performed on 4 patients. Combined right/or left lobectomy with caudate lobectomy was carried out on 16 patients. The levels of serum Aspartate Aminotransferase (AST) and Alanine Aminotransferase (ALT) decreased significantly. Icterus was significantly improved and the serum TB level decreased postoperatively. Hepatic abscess occurred in 3 patients. One patient with bile leakage died of pneumonia 2 months post operation. The remaining patients recovered three months after operation to a life close to normal conditions.

Conclusion: Extended high hilar resection and enlarged hepatic portal enterostomy was applied for the treatment of hilar cholangiocarcinoma patients and it had a positive outcome in many patients.

Keywords: High hilar cholangiocarcinoma; Portal parenchyma enterostomy; AST; ALT

OPEN ACCESS

*Correspondence:

Abdul Qahar Saleh, Department of Hepatobiliary, Qilu Hospital of Shandong University, 107 Wenhua West Road, Lixia, Jinan, Shandong, China, Tel: 8618560082080; E-mail: saleh23abdul@gmail.com

Received Date: 18 Nov 2019

Accepted Date: 16 Dec 2019

Published Date: 20 Dec 2019

Citation:

Saleh AQ, Yu-Xin C, Shang Lei N, Ling Yu G, Fitrat H. Extended High Hilar Resection and Enlarged Hepatic Portal Enterostomy in the Treatment of Hilar Cholangiocarcinoma. *World J Surg Surgical Res.* 2019; 2: 1182.

Copyright © 2019 Abdul Qahar Saleh. This is an open access article distributed under the Creative Commons Attribution License, which permits unrestricted use, distribution, and reproduction in any medium, provided the original work is properly cited.

Introduction

The treatment of hilar cholangiocarcinoma continues to evolve, and improved survival time and a better life quality remains the primary aim. Hepatobiliary resection has become common in treating such patients [1-5], but radical high resection increases the difficulty in traditional biliary-enterostomy [3-5]. We performed extended high hilar resection and enlarged hepatic portal-enterostomy on 51 patients with hilar cholangiocarcinoma and analyzed their clinical data.

Methods

Patients

From March 2016 to March 2018, 56 hilar cholangiocarcinoma patients were referred for surgical treatment. Extended high hilar resection and enlarged hepatic portal-enterostomy was performed on 51 cases of hilar cholangiocarcinoma patients. One patient with cirrhosis was not included because the pathological diagnosis was hepatic cellular cancer with the invasion of hilar bile duct. Stent enterostomy was performed on 5 patients with metastasis in the abdomen cavity. Duplex Ultrasonography (US), Computed Tomography (CT) and/or Magnetic Resonance Cholangiopancreatography (MRCP) were applied to evaluate the range of invasion and distant metastasis of tumors. Percutaneous Transhepatic Biliary Drainage (PTCD) and bile refusion were performed on patients with a bilirubin level higher than 400 mmol/L and Child Grade B or

Table 1: Demographic of the patients.

Variable	Value
Age (years)	35-78
Sex (M: F)	28:23
TIBL ($\mu\text{mol/L}$)	132-623
Type of surgery:	
•Partial R.H.A.	11
• P.V. resection	04
•R/LLCL	16
Operative time (minutes)	190-230
Hospital stay (days)	12-30
Post-operative complications:	
• Hepatic abscess	03
• Bile leakage	01

R/LLCL: Right/Left Lobectomy and Caudate Lobectomy

above. Endoscopic Retrograde Cholangiopancreatography (ERCP) was performed when necessary. The Total Bilirubin (TB) level ranged from 132 to 623 mmol/L. Vitamin K was administered at a dose of 30 mg/day for 3 to 15 days before operation. Symptoms of anemia, hypoproteinemia, and electrolyte disorders were treated and improved. Malnourished patients were given total parenteral nutrition preoperatively (Table 1).

Surgical procedure

The abdomen was entered and explored thoroughly, through a right lateral subcostal incision with left extension to the xiphoid. The ligamentum teres was elevated and the inferior surface of the liver was exposed. Precise assessment of tumour extension was evaluated. Careful palpation of the liver was performed to rule out suspected masses within the liver. Some lesser omentum was dissected and the lesser sac was accessed to palpate the caudate lobe. A Kocher manoeuvre was performed in some patients when the retroduodenal lymph nodes were suspected with metastases [3,4].

The common bile duct was transected above the duodenum generally and turned upward. The lymph node, fat, nerve fibres, and other connective tissue along the common bile duct were cleared to achieve skeletonization of the hepatoduodenal ligament if radical resection was possible. The entire extrahepatic biliary apparatus and adjacent lymphatic tissues were turned upward to expose the portal vein. The dissection was continued upward towards the hilum, skeletonizing the portal vein and hepatic artery. It was easier to dissect the posterior aspect of the bile duct tumour from the portal vein and hepatic arteries to the level of the bifurcation of the portal vein provided that there was no invasion to the vessels. The gallbladder was freed from the liver, and the liver hilum was fully exposed anteriorly by taking down the gallbladder. At this point, the proximal extent of the tumour was assessed by palpation.

The incision was made on the liver surface with the resection of at least 1 cm above liver tissue at the base of segment IV. The hepatic parenchyma was dissected using an electric scalpel combined with cavitron ultrasonic surgical aspirator. Hepatic parenchyma bleeding was controlled by electric coagulation and suturing. The branches of bile duct were transected using scalpel or scissors. Some tissues of caudate lobe were resected, combined right/or left lobectomy with caudate lobectomy was carried out when necessary (Figure 1). Rapid frozen section was performed to observe whether the margin of

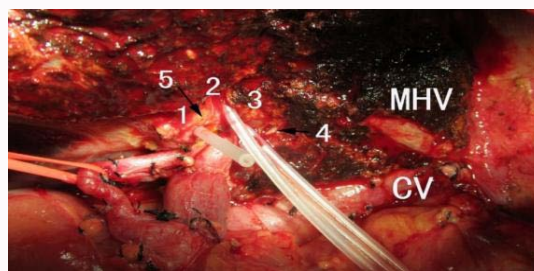

Figure 1: Radical high hilar resection of hepatic hilar cholangiocarcinoma combined with left hepatectomy (1-5: bile duct branches, VC: Vena Cava; MHV: Middle Hepatic Vein).

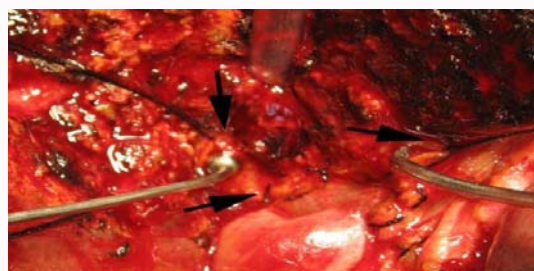


Figure 2: Radical resection of hepatic hilar cholangiocarcinoma together with the hepatic portal liver tissue. The bile duct branch orifice was sutured together with the surrounding liver tissue (black arrows).

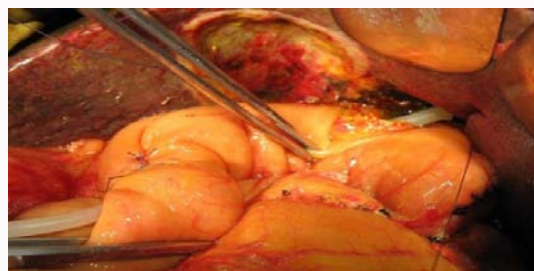


Figure 3: Completion of the posterior wall of the hepatic parenchyma-enterostomy anastomosis.

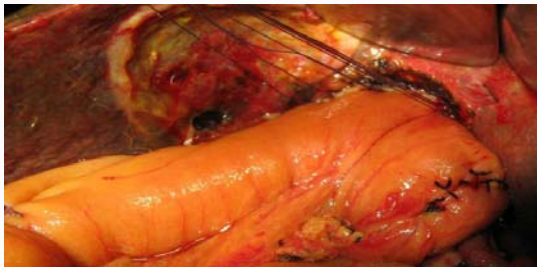
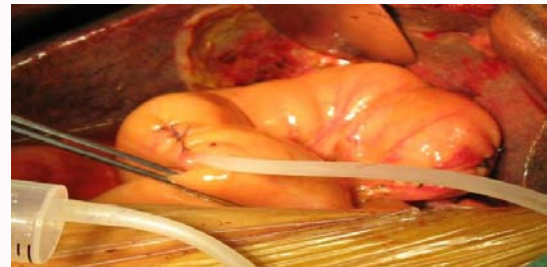
resection was tumour-free if radical resection was possible. The bile ducts with a diameter of over 5 mm were exposed and the wall was sutured with the surrounding tissues (Figure 2).

When radical resection was possible, then the branches of portal and/or hepatic artery were invaded, the invaded branch was ligated and resected. Partial resections of the portal branch or portal vein were possible. If partial hepatectomy was required, the ipsilateral branch of portal vein and hepatic artery were ligated and en bloc caudate lobectomy was performed. When palliative biliary drainage was conducted, tumour tissue was resected as much as possible; however, the resection line should be assessed carefully to avoid heavy hemorrhage.

A Roux-en-Y loop of jejunum was prepared and brought up in a retrocolic fashion (approximately 40 cm distal to the ligament of Teres). Anastomosis was carried out in an end-to-side fashion between the hepatic parenchyma incision line and the side of jejunum loop using a single layer of 0 silk. The anastomotic opening included all of the openings of the bile ducts without ligation of any biliary radicles. Suture was performed with a 1/2 radian suture needle, and the knot was tied in situ with moderate tension to avoid laceration of

Table 2: Karnofsky Performance Status Scale Criteria Rating (%).

Definition	Score	Criteria
Able to carry on normal activities and to work; no special care needed	100	Normal, no complain, no evidence of disease
	90	Able to carry on normal activity, minor signs or symptoms of disease
	80	Normal activity with effort, some signs or symptoms of disease
Unable to work, able to live at home and care for most personal needs, varying amount of assistance needed	70	Cares for self, unable to carry on normal activity or to do active work
	60	Requires occasional assistance, but is able to care for most personal needs
	50	Requires considerable care and frequent medical assistance
Unable to care for self, requires equivalent of institutional or hospital care; disease may be progressing rapidly	40	Disabled, requires special care and assistance
	30	Severely disabled, hospital admission is indicated although death not imminent
	20	Very sick, hospital admission necessary, active supportive treatment necessary
	10	Moribund, fatal processes progressing rapidly
	0	Dead

**Figure 4:** Completion of the anterior wall of the hepatic parenchyma-enterostomy anastomosis.**Figure 5:** Injection of air into jejunum loop for leakage test of the anastomosis.

hepatic tissue. Posterior wall anastomosis was a difficult part of the surgery because there were few suturable parts of liver tissue anterior to inferior vena cava. Suture of the liver caudate tissue was not performed too deep as a result of the risk of injury to the inferior vena cava. Two to three stents were inserted into the bile duct branches with a diameter greater than 5 mm and were fixed using one single interrupted suture of 4-0 Vicryl suture with the bile duct wall, and one stent tube was pulled out through the wall of the jejunum loop (Figure 3). The intestinal wall and hepatic parenchyma were sutured together for anterior wall anastomosis of the jejunum loop with interrupted sutures, and all biliary radicles were drained into the hepatic portal bile lake (Figure 4). When palliative resection was performed, it was possible to suture the post wall of the jejunum with the tumour tissue. After completion of the anastomosis, air was injected into the jejunum loop from the stent tube to test whether there was leakage of the hepatic parenchyma-enterostomy anastomosis (Figure 5). Drainage was routinely employed near the anastomosis [3,4].

Post-operative management

Nutritional support was given postoperatively for three days to patients with the balance of calories, protein, fat, trace elements and vitamins. It was administered by the peripheral intravenous route. If a nasoenteric tube was placed before operation, early enteral nutrition was utilized. Drainage was removed postoperatively. Stent tube was pulled out, after a cholangiography was obtained with injection of contrast medium across it.

Results

The study included 28 male and 23 female patients with ages ranging from 35 to 78 years old. All of the fifty-one patients underwent

high hilar resection and hepatic hilar parenchyma-enterostomy anastomosis. Five to twelve biliary radicles were exposed. Partial tumour resection and palliative biliary drainage was conducted on 17 patients, and one patient had a bile fistula for 2 months. Combined right/left hepatectomy with caudate lobectomy was performed on 16 patients. Eleven patients underwent right hepatic artery resection and partial resection of portal vein was performed on 4 patients. The operation time ranged from 190 min to 430 min, and the amount of bleeding was from 150 ml to 1200 ml. Two weeks post-surgery, the levels of serum aspartate aminotransferase and alanine aminotransferase decreased significantly. Icterus was significantly improved and the serum TB level decreased postoperatively. Postoperative complications occurred in 11 patients (one case of anastomosis leakage, five cases of wound infection, 3 patients with hepatic abscess, one case of hemobilia, one case of bile leakage from the hepatic transection surface). The postoperative hospitalizations of patients were from 12 to 30 days. The patient with bile leakage died of pneumonia two months post operation. The performances of the patients were evaluated according to Karnofsky Performance Scale. The average Karnofsky score was 83 (ranging from 69-100), indicating that some patients had symptoms or signs but could engage in normal activities. The score increased significantly 2 months post operation (Table 2).

Discussion

Cholangiocarcinoma accounts for 3% of all gastrointestinal cancers, and about 50% to 60% of them are hilar cholangiocarcinoma which occurs at the bifurcation of the left and right hepatic ducts. The tumors grow slowly, and many of them are diagnosed as advanced lesions with low radical resection rates and long-term survival rates. Local recurrence and re-obstructive jaundice are the main causes

of morbidity and mortality post operation. The purposes of the management for these patients are to improve the quality of life and prolong the survival period. Surgical treatment is one of the major options, and expanding the scope of resection and postponing the reobstruction after biliary-enteric restoration, are the main measures. The main objectives in the therapy of hilar cholangiocarcinoma are complete tumour excision with negative margins if possible, and restoration of biliary-enteric continuity [6-11]. If resection is not clearly unfeasible, patients should be fully evaluated for possible curative resection before any intervention is performed since stent-associated infection and inflammation renders assessment and exploration difficult [1,2,6,11,12]. If resection is clearly not feasible, transtumoral drainage or paratumoral surgical bypass can be performed traditionally and offer palliation [1,7,11,13].

Traditionally, the liver hilum is fully exposed anteriorly by taking down the gallbladder and lowering the hilar plate by incising Glisson's capsule along the base of segment IV [13-17]. It is not infrequent that removal of the tumor results in discontinuity of the right anterior and posterior sectoral ducts and/or separation of one or more caudate ducts from the left hepatic duct. In previous experience for hilar cholangiocarcinoma, after resection of tumors, the large bile ducts were refitted and end-to-side anastomosed with the jejunum and some small bile ducts (less than 1 mm to 2 mm) were drained not satisfactory or ligated. Expansion of the proximal bile ducts would compress the portal vein in the same Glisson's sheath. This procedure often led to portal hypertension and cholestasis, which increased the incidence of cholangitis and bacterial infections [13-15]. In this study, the incision was made at, at least 1 cm above the Glisson's capsule along the base of segment IV to resect more hepatic tissues and achieve tumour-free margins [3,4]. Portal parenchyma-enterostomy was performed without any bile duct integration or ligation. All bile ducts converged into the hepatic portal bile lake, and the bilirubin level of patients dropped close to normal levels after surgery. This procedure also provided effective biliary drainage in palliative resection patients.

Hepatoportoenterostomy (Kasai portoenterostomy) was first proposed by Morio Kasai in 1974 for the treatment of children with congenital biliary atresia [18], and since then, it has been used for the treatment of high bile duct injury and cholangiocarcinoma [19]. Some modifications have been made on the basis of previous experiences. The main differences lie in that: 1) The hilar plate was conserved and after exposure of the hilar bile duct in the surgery procedure described by Kasai, fibrous tissue was anastomosed with the jejunum, whereas in this procedure, the hilar tissues were skeletonized, and the hilar plate, part of the caudate lobe, and the surrounding portal parenchyma were resected. 2) There were few or no hilar bile ducts in congenital biliary atresia patients, whereas in hilar cholangiocarcinoma patients, there were more than 5 inflatable hilar bile duct radicals. 3) Higher hilar resection should be performed to achieve tumour-free margins in hilar cholangiocarcinoma patients. 4) The posterior wall was anastomosed with the resection surface of the caudate lobe. 5) Some hilar cholangiocarcinoma patients were with inflammation around the hepatic hilar.

Funding

Manuscript has been funded by National Science Foundation of Shandong Province of China (2016GSF201180).

References

1. Huang ZQ. Present status and prospection of surgical treatment for hilar

cholangiocarcinoma. *Chinese J Bases and Clin Gen Surg.* 2005;12:317-20.

- Endo I, Shimada H, Sugita M, Fujii Y, Morioka D, Takeda K, et al. Role of three dimensional imaging in operative planning for hilar cholangiocarcinoma. *Surgery.* 2007;142(5):666-75.
- Chen YX, Liu EY, Zhang XG, Xu KS, Niu J, Shou NH. Hilar cholangiocarcinoma resection and hepatic portal enterostomy. *Chinese J Current Adv Gen Surg.* 2008;11(3):13-6.
- Cheng Y, Chen Y, Chen H. Application of portal parenchyma-enterostomy after high hilar resection for Bismuth type IV hilar cholangiocarcinoma. *Am Surg.* 2010;76(2):182-7.
- Chen XP, Lau WY, Huang ZY, Zhang ZW, Chen YF, Zhang WG, et al. Extent of liver resection for hilar cholangiocarcinoma. *Br J Surg.* 2009;96(10):1167-75.
- Kawasaki S, Imamura H, Kobayashi A, Noike T, Miwa S, Miyagawa S. Results of surgical resection for patients with hilar bile duct cancer: application of extended hepatectomy after biliary drainage and hemihepatic portal vein embolization. *Ann Surg.* 2003;238(1):84-92.
- Tsao JI, Nimura Y, Kamiya J, Hayakawa N, Kondo S, Nagino M, et al. Management of hilar cholangiocarcinoma: comparison of an American and a Japanese experience. *Ann Surg.* 2000;232(2):166-74.
- Seyama Y, Kubota K, Sano K, Noie T, Takayama T, Kosuge T, et al. Long-term outcome of extended hemihepatectomy for hilar bile duct cancer with no mortality and high survival rate. *Ann Surg.* 2003;238(1):73-83.
- Sun Y, Wu ZY, Hao CY, Huang XF, Wang K, Bao Q, et al. Clinical analysis of curative resection with hemihepatectomy for advanced hilar cholangiocarcinoma [in Chinese]. *Zhonghua Yi Xue Za Zhi.* 2008;88:527-30.
- Konstadoulakis MM, Roayaie S, Gomatos IP, Labow D, Fiel MI, Miller CM, et al. Aggressive surgical resection for hilar cholangiocarcinoma: is it justified? Audit of a single center's experience. *Am J Surg.* 2008;196(2):160-9.
- Seyama Y, Makuuchi M. Current surgical treatment for bile duct cancer. *World J Gastroenterol.* 2007;13(10):1505-15.
- Arakura N, Takayama M, Ozaki Y, Maruyama M, Chou Y, Kodama R, et al. Efficacy of preoperative endoscopic nasobiliary drainage for hilar cholangiocarcinoma. *J Hepatobiliary Pancreat Surg.* 2009;16(4):473-7.
- Khan AZ, Makuuchi M. Trends in the surgical management of Klatskin tumours. *Br J Surg.* 2007;94(4):393-4.
- Shigeta H, Nagino M, Kamiya J, Uesaka K, Sano T, Yamamoto H, et al. Bacteremia after hepatectomy: an analysis of a single-center, 10-year experience with 407 patients. *Langenbecks Arch Surg.* 2002;387(3-4):117-24.
- Miyazaki M, Ito H, Nakagawa K, Ambiru S, Shimizu H, Shimizu Y, et al. Aggressive surgical approaches to hilar cholangiocarcinoma: hepatic or local resection? *Surgery.* 1998;123(2):131-6.
- Yokoyama Y, Nagino M, Nishio H, Ebata T, Igami T, Nimura Y, et al. Recent advances in the treatment of hilar cholangiocarcinoma: portal vein embolization. *J Hepatobiliary Pancreat Surg.* 2007;14(5):447-54.
- Kondo S, Katoh H, Hirano S, Ambo Y, Tanaka E, Kawarada Y, et al. Wedge resection of the portal bifurcation concomitant with left hepatectomy plus biliary reconstruction for hepatobiliary cancer. *J Hepatobiliary Pancreat Surg.* 2002;9(5):603-6.
- Kasai M. Treatment of biliary atresia with special reference to hepatic porto-enterostomy and its modifications. *Prog Pediatr Surg.* 1974;6:5-52.
- Karakousis CP, Douglass HO Jr. Hilar hepatojejunostomy in resection of carcinoma of the main hepatic duct junction. *Surg Gynecol Obstet.* 1977;145(2):245-8.