



# Bilateral Upper Lobe Occlusion as a Pulmonary Manifestation of Granulomatosis with Polyangiitis

Barros PP\*

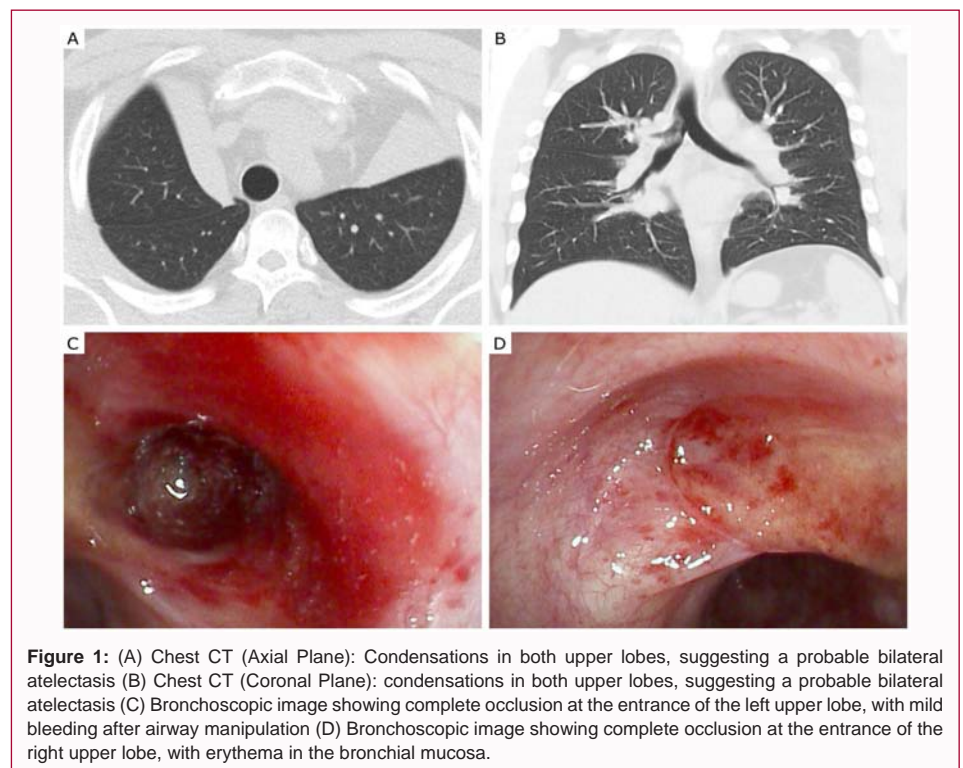
University Hospital Center of the Algarve - Faro Hospital, Portugal

## Clinical Image

A Twenty-four-year-old male, non-smoker, medical history of granulomatosis with polyangiitis, with cavitated bilateral pulmonary nodules identified the previous year. In the outpatient follow up, the chest CT revealed condensations in both upper lobes, suggesting a probable bilateral atelectasis (Figure 1A, 1B). A bronchoscopy was performed, revealing a complete occlusion of both upper lobes (Figure 1C, 1D). Biopsies showed unspecific chronic inflammation. Subsequently, the patient was submitted to rigid bronchoscopy, recanalizing both upper lobes after puncturing of the occlusion and using balloon dilation. Chest CT showed resolution of the atelectasis one month after the procedure.

Pulmonary involvement in granulomatosis with polyangiitis occurs at some stage of the disease in 90% of patients, with a wide spectrum of patterns [1]. Concentric wall thickening is a possible manifestation that may lead to airway stenosis, but complete bronchial occlusion is a very rare manifestation of the disease, with only a few cases described in the literature [2].

In this clinical case, a total occlusion was found in the entrance of both upper lobes. The bronchoscopy played an important role in the diagnosis and treatment of this condition, managing to reopen both upper lobes after rigid bronchoscopy.



**Figure 1:** (A) Chest CT (Axial Plane): Condensations in both upper lobes, suggesting a probable bilateral atelectasis (B) Chest CT (Coronal Plane): condensations in both upper lobes, suggesting a probable bilateral atelectasis (C) Bronchoscopic image showing complete occlusion at the entrance of the left upper lobe, with mild bleeding after airway manipulation (D) Bronchoscopic image showing complete occlusion at the entrance of the right upper lobe, with erythema in the bronchial mucosa.

## OPEN ACCESS

### \*Correspondence:

Pedro Pereira Barros, University Hospital Center of the Algarve - Faro Hospital, Portugal, E-mail: pedro34621@gmail.com

Received Date: 18 Nov 2022

Accepted Date: 13 Dec 2022

Published Date: 16 Dec 2022

### Citation:

Barros PP. Bilateral Upper Lobe Occlusion as a Pulmonary Manifestation of Granulomatosis with Polyangiitis. *World J Surg Surgical Res.* 2022; 5: 1432.

Copyright © 2022 Barros PP. This is an open access article distributed under the Creative Commons Attribution License, which permits unrestricted use, distribution, and reproduction in any medium, provided the original work is properly cited.

## References

- Allen SD, Harvey CJ. Imaging of Wegener's granulomatosis. *Br J Radiol.* 2007;80(957):757-65.
- Tandon A, Magge A, Nadler E, Mutneja R, Ibrahim O. Stenosis of the bronchial tree due to granulomatosis with polyangiitis. *Chest.* 2018;154(4):907.