



## A Multidisciplinary Algorithm in the Non-Operative Management of Upper GI Complications – A Retrospective Cohort Study

Koshy RM\*

Department of General Surgery, University Hospitals of Coventry and Warwickshire NHS Trust, UK

### Abstract

**Introduction:** The non-operative management of UGI complications lacks consensus, despite being the subset that requires a concerted multidisciplinary approach. The aim of this study is to propose an algorithm of management, with early endoscopy and interventional radiology as adjuncts to surgical interventions.

**Methods:** This retrospective cohort describes the management of 37 patients over a 5 year period with the evolution of a multidisciplinary team and an algorithm of management in a tertiary UGI centre. The cohort included 15 bariatric, 12 Cancer and 10 Oesophageal perforation patients. The primary outcome was the morbidity profile and mortality the secondary outcome.

**Results:** The median number of stents used per patient across the groups was two. The leak resolution time was 34, 52.5 and 60.5 days among the cancer, bariatric and perforation groups, respectively. Radiological drains were required in about 36% of patients across the groups. Nutritional access was established with Naso-Jejunal tubes with overlapping TPN in the bariatric and perforation groups, while the cancer group had Feeding Jejunostomy tubes inserted during their resections. The mean duration of hospital stay was 29.5, 41.5 and 63 days respectively. Three (8%) patients developed major stent-related complications (Clavien-Dindo Grade 3b) requiring reoperation. There were no mortalities in the cohort.

**Conclusion:** Though heterogeneous, UGI complications have common management principles. The non-operative management algorithm with endoscopy and adjuncts is still an aggressive, yet conservative approach with prompt control of sepsis and establishment of early nutrition. This multidisciplinary approach is an effective means of resolution with minimal morbidity and mortality.

**Keywords:** Upper GI complications; Non-operative management; Endoscopic algorithm; Multidisciplinary approach

### Introduction

Advancement in technology and techniques has seen a lot more complex Upper Gastrointestinal procedures, with equally complex complications, when associated. Upper GI procedures have their own subset of complications, which span across a very heterogenous group, from bariatrics to cancer to the emergency oesophageal perforations. These patients can be critically unwell and the lack of a consensus in the acute management and the need for unprecedented long-term care plans makes it challenging.

The majority of UGI disruptions are constituted of oesophageal perforations (Iatrogenic - 60% and spontaneous-15%), anastomotic leaks (10% to 20%) and Gastric sleeve staple line leaks (2%) [1,2]. The associated morbidity and mortality are high with rates of up to 60% and 40% respectively [3].

Management of these complex complications demands a multidisciplinary and algorithmic approach. Few of them are acutely unstable and septic; needing a surgical intervention, but the majority of them will need a non-operative approach. In them, the aggressive management is often conservative in approach, with multi-modal strategies. The collaboration between surgeons, endoscopists, interventional radiologists, intensivists and nutritionists determines the outcome. Endoscopic and radiological interventions augment surgical interventions to obtain the best

### OPEN ACCESS

**\*Correspondence:**

Koshy RM, Department of General Surgery, University Hospitals of Coventry and Warwickshire NHS Trust, UK,

E-mail: [renol.koshy@nhs.net](mailto:renol.koshy@nhs.net)

**Received Date:** 13 Oct 2020

**Accepted Date:** 09 Nov 2020

**Published Date:** 13 Nov 2020

**Citation:**

Koshy RM. A Multidisciplinary Algorithm in the Non-Operative Management of Upper GI Complications – A Retrospective Cohort Study. *World J Surg Surgical Res.* 2020; 3: 1259.

**Copyright** © 2020 Koshy RM. This is an open access article distributed under the Creative Commons Attribution License, which permits unrestricted use, distribution, and reproduction in any medium, provided the original work is properly cited.

possible clinical resolution with minimal morbidity and mortality. With growing skills and techniques, multiple systematic reviews propose early endoscopic interventions with adjuncts and endorse their safety profile [4-6].

The aim of this retrospective, observational study is to describe an algorithm, based on improvements over 5 years of managing this complicated cohort. The process led to has meant an interdisciplinary collaboration and establishment of a multidisciplinary team at the tertiary university hospital.

## Methods

The retrospective cohort included 37 patients between 2013 and 2018 with upper GI complications (38 events) at the Upper GI unit at a tertiary level university hospital within the NHS, UK. Their morbidity analysis in the first year post resolution was recorded. The non-operative management strategies involved a combination of radiological drains, endoscopic stents and adjuncts. The level of care was determined by the clinical severity at presentation and the necessity of monitoring and organ support. The cohort included a varied mix of benign and malignant; elective and emergency pathologies as described below (Figure 1).

The bariatric group consisted of 13 Post-Sleeve Gastrectomy Leaks (PSGL) and 2 narrowing of the sleeve at the incisura, which needed endoscopic stenting.

The cancer group consisted of anastomotic leaks following 11 Ivor-Lewis Oesophago-Gastric resection for lower oesophageal cancer and 1 Total Gastrectomy.

The oesophageal perforation group consisted of 7 iatrogenic and 3 spontaneous perforations.

All patients above 18 years of age with upper GI complications suitable for non-operative management were included in the study, from a prospectively maintained database of endoscopic interventions. All patients who required immediate surgery following an upper GI complication were excluded. The follow-up was up to symptom resolution, with either endoscopic or radiologic confirmation. The primary outcome was the morbidity profile and mortality the secondary outcome.

This being an observational study with no patient identifiable data collected, required no patient consent or ethical clearance. All

documentation was based on the STROBE guidelines for reporting observational cohort studies (3). The study was registered on <https://www.researchregistry.com/browse-the-registry#home/> with the ID-research registry 5918.

## Results

Though being heterogeneous in aetiology, the group had common themes they subscribed to. All of them had features of sepsis requiring the Sepsis-6 bundle with broad spectrum IV antibiotics as per trust policies [7]. The intensivists were involved in the management of those who required additional monitoring and organ support at levels 2 to 3. The diagnosis was established by either Contrast Enhanced CT scans or water contrast studies.

Early endoscopic assessments were done on an urgent basis within 24 h of the diagnosis to assess the location and size of the defect. In appropriate cases, a covered stent was placed for source control. The addition of adjuncts such as APC, clipping and NJ tubes made endoscopic interventions multimodal and more effective. Post-stenting, contrast studies were done to confirm the technical success of the procedure, defined by its position in relation to the defect and containment of contrast leak. The stents needed to be exchanged at 2 weeks to prevent embedment and erosion. The median number of stents per patient was two, across the groups until clinical resolution defined by no leak of contrast on water soluble contrast study and ability to commence on enteral feeding. The median duration of stent days was 34, 52.5 and 60.5 days among the cancer, bariatric and perforation groups, respectively.

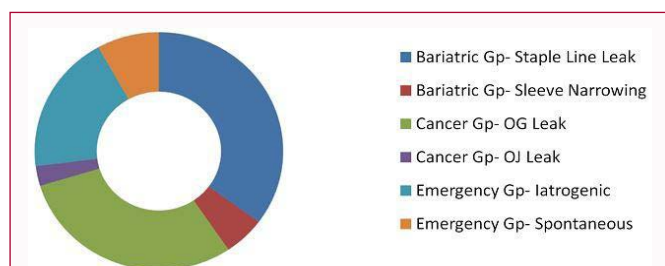
Simultaneous radiological interventions to help with drainage of collections were documented in about 36% of patients across the groups. A few patients also required more than one drain put in for complex and recurrent collections. This further helped in control of sepsis and formation of a controlled fistula.

Nutritional assessment and planning was initiated as required. The cancer group usually had a tube in the form of either a feeding jejunostomy with Oesophagectomies [2] or a Naso-jejunal for Gastrectomies [4]. The bariatric and the perforation [8] groups needed Naso-jejunal tubes placed during the endoscopic assessment, for enteral feeding. A small group however required an overlap of TPN and two of them went home with it. Patients were allowed to commence phased oral intake based on their clinical progression and contrast studies, done on follow-up till resolution.

The median length of stay in hospital amongst the cancer, bariatric and perforation groups were 41.5, 29.5 and 63 days, with a median readmission rate of 2, 3 and 4 times respectively.

The morbidity analysis of the subset revealed three patients (8%) with significant (Clavien-Dindo grade 3b) stent related complications. Two of these belonged to the oesophageal anastomotic leak group, where one patient developed stent embedment with erosion and was referred to a specialist centre at 12 months, while the other patient developed a stricture that required regular endoscopic dilations until resolution at 6 months. The third patient belonged to the perforation group, whereby the stent migrated and led to small bowel obstruction, needing an emergency laparotomy.

All these patients were regularly followed up, as often as required, post resolution. This study documented their progress in the first year post resolution for morbidity analysis.



**Figure 1:** The cohort included a varied mix of benign and malignant; elective and emergency pathologies.

1. Bariatric group (15) - Post-Sleeve Gastrectomy leak (PSGL) -13 Narrow Sleeve (Gastric Incisura) - 2
2. Cancer group (12) - Oesophgo-Gastric Anastomotic Leak - 11 Oesophago-Jejunal Anastomotic Leak- 1
3. Oesophageal perforation group (10)- Iatrogenic - 7 Spontaneous – 3

**Table 1:** The table here summarizes the parameters of the different groups.

Comparison parameters	Bariatric group (15)	Cancer group (12)	Emergency group (10)
Number of stents used (Median)	2	2	2
Resolution time (Median-Days)	34	52.5	60.5
Use of radiologically placed drains	36%	36%	38%
Route of nutrition	Naso-jejunal tube ± TPN	Feeding jejunostomy	Naso-jejunal tube ± TPN
Hospital stay (Median-Days)	29.5	41.5	63
Stent related Morbidity	0	2 (embedment and stricture)	1 (small bowel obstruction)

The table (Table 1) here summarizes the parameters of the different groups as mentioned.

## Discussion

The heterogeneous nature of the cohort adds to the strength of the pathway developed as it seems to have principles that are common and transferable. The multidisciplinary and algorithmic approach in the non-operative management of upper GI complications though conservative is aggressive. There was good clinical resolution with minimal morbidity and mortality.

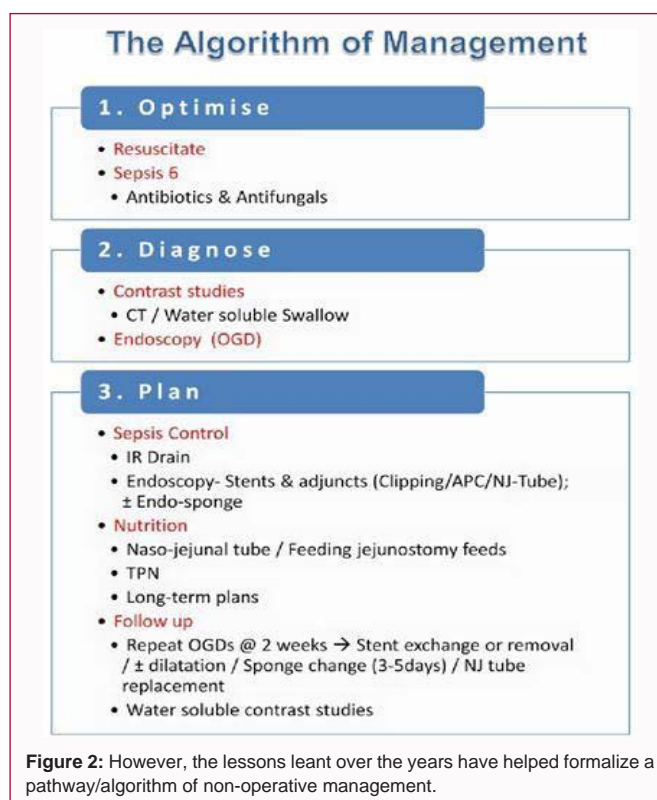
Endoscopic stenting with its adjuncts has shown a great therapeutic value with a growing safety profile, with growing experience. A recent systematic review of endoscopic stents in oesophageal pathology including 66 studies and 1,752 patients [5] established their low morbidity profile, with stent migration of 12%, perforation at 0.7%, erosion of 4%, bleeding at 0.6% and overall stricture rates of 2%. The surgical re-intervention rate was only 7% irrespective of the stent type (plastic or metal) and took a median of 40 days to heal. These measures corroborate our findings too. The mortality rate in the stented group was 7% which is a huge improvement from about 20% as reported in literature in the non-stented group [9]. Also metal stents performed better than their plastic counterparts in technical and clinical success rates [5]. The metal stents however, have a higher risk of embedment and erosion; hence need to be replaced every 2 weeks, until resolution.

Newer modalities like the endoscopic vacuum assisted closure aka endo-sponge/E-VAC, with growing therapeutic usage has further added to the armamentarium of the endoscopist [10]. A systematic review of 11 studies and 210 patients reported clinical success rates of more than 90% in oesophageal perforation and anastomotic leaks with the technique [11].

The radiological interventions in our group were around 36%, while the majority of studies documented 10%, highlighting the multi-modal and aggressive conservative measures applied here.

The World Society Emergency Society guidelines for the management of oesophageal emergencies also advocate the conservative non-operative measures in patients who are hemodynamically stable, with early presentations, contained disruptions and limited contamination of surrounding spaces. Direct repair is the preferred option, while those who don't meet the above criteria and if repair is not feasible (large disruption, delayed surgery, preexistent esophageal disease), external drainage, esophageal exclusion or resection are possible options [8].

Within the bariatric group, the operative management of post-Sleeve Gastrectomy leaks is debatable. The growing expertise in endoscopic techniques seems to push the trend towards a more non-operative approach, especially in stable patients with minimal



contamination [12].

With evolution of techniques and growing expertise in the skill set in the management of these complex complications, the results have improved. This study also demonstrates the maturing of a team and its concerted efforts in the evolution of the algorithm. Being a single centre, and the same team, has minimized the variation and is its strength, despite the learning curve. The limitation of the study is its retrospective nature and the heterogeneous groups, which make extrapolation and statistical analysis difficult. However, the lessons learnt over the years have helped formalize a pathway/algorithm of non-operative management, which is detailed below (Figure 2).

## Conclusion

The management of upper GI complications, though heterogeneous in nature have common transferable management principles. An aggressive-conservative approach with prompt control of sepsis and establishment of early enteral nutritional regimens is crucial. Endoscopic stenting is most effective with its adjuncts, and has proved to have a minimal morbidity profile. A multidisciplinary and algorithmic approach helps achieve best outcomes with minimal morbidity and mortality.

## References

1. Sdralis EIK, Petousis S, Rashid F, Lorenzi B, Charalabopoulos A. Epidemiology, diagnosis, and management of esophageal perforations: Systematic review. *Dis Esophagus*. 2017;30(8):1-6.
2. Gagner M, Kemmeter P. Comparison of laparoscopic sleeve gastrectomy leak rates in five staple-line reinforcement options: A systematic review. *Surg Endosc*. 2020;34(1):396-407.
3. Messenger M, Warlaumont M, Renaud F, Marin H, Branche J, Piessen G, et al. Recent improvements in the management of esophageal anastomotic leak after surgery for cancer. *Eur J Surg Oncol*. 2017;43(2):258-69.
4. Dasari BV, Neely D, Kennedy A, Spence G, Rice P, Mackle E, et al. The role of esophageal stents in the management of esophageal anastomotic leaks and benign esophageal perforations. *Ann Surg*. 2014;259(5):852-60.
5. Kamarajah SK, Bundred J, Spence G, Kennedy A, Dasari BVM, Griffiths EA, et al. Critical appraisal of the impact of oesophageal stents in the management of oesophageal anastomotic leaks and benign oesophageal perforations: An updated systematic review. *World J Surg*. 2020;44(4):1173-89.
6. Chang J, Sharma G, Boules M, Brethauer S, Rodriguez J, Kroh MD, et al. Endoscopic stents in the management of anastomotic complications after foregut surgery: New applications and techniques. *Surg Obes Relat Dis*. 2016;12(7):1373-81.
7. Sepsis: Recognition, diagnosis and early management. NICE guideline [NG51] Published date: 13 July 2016 last updated: 13 September 2017.
8. Chirica M, Kelly MD, Siboni S, Aiolfi A, Riva CG, Asti E, et al. Esophageal emergencies: WSES guidelines. *W J Emerg Surg*. 2019;14:26.
9. Rutegård M, Lagergren P, Rouvelas I, Lagergren J. Intrathoracic anastomotic leakage and mortality after esophageal cancer resection: A population-based study. *Ann Surg Oncol*. 2012;19:99-103.
10. Pournaras DJ, Hardwick RH, Safranek PM, Sujendran V, Bennett J, Macaulay GD, et al. Endoluminal Vacuum therapy (E-Vac): A treatment option in oesophagogastric surgery. *World J Surg*. 2018;42(8):2507-11.
11. Kuehn F, Loske G, Schiffmann L, Gock M, Klar E. Endoscopic vacuum therapy for various defects of the upper gastrointestinal tract. *Surg Endosc*. 2017;31(9):3449-58.
12. Vargas EJ, Dayyeh BKA. Keep calm under pressure: A paradigm shift in managing postsurgical leaks. *Gastrointestinal Endosc*. 2018;87(2):438-41.