



The Use of Angiotensin II for Vasodilatory Shock in a Jehovah's Witness Patient Undergoing Thoracic Surgery: A Case Report

Connie J Lin¹, Kyung-Min Lee¹, Silviu C Diaconu², Gregory D Trachiotis^{2*} and Eric R Heinz^{1*}

¹Department of Anesthesiology and Critical Care Medicine, The George Washington University Hospital, USA

²Department of Cardiothoracic Surgery, The George Washington University Hospital, USA

Abstract

Perioperative management of shock can present a major anesthetic challenge in critically ill patients as prolonged hypotension can lead to multi-system organ failure and death. Despite standard therapy of fluid resuscitation, and administration of catecholaminergic vasopressors and vasopressin to maintain blood pressure goals, the morbidity and mortality of patients with shock remains high. We report the successful use of perioperative Angiotensin II as monotherapy for a patient with vasodilatory shock who was at high risk for adverse events with the standard management of fluid resuscitation and catecholaminergic vasopressor therapy.

OPEN ACCESS

*Correspondence:

Eric R Heinz, Department of Anesthesiology and Critical Care Medicine, The George Washington University Hospital 900 23rd Street, Suite G 2092, Washington, DC, 20037, USA,

E-mail: heinz.md.phd@gmail.com

Gregory D Trachiotis, Department of Cardiothoracic Surgery, The George Washington University, The Veterans Affairs Medical Center, 50 Irving St, NW Suite 2A163 Washington, DC 20422, USA,

E-mail: Gregory.trachiotis@va.gov

Received Date: 12 Sep 2019

Accepted Date: 25 Oct 2019

Published Date: 05 Nov 2019

Citation:

Lin CJ, Lee K-M, Diaconu SC, Trachiotis GD, Heinz ER. The Use of Angiotensin II for Vasodilatory Shock in a Jehovah's Witness Patient Undergoing Thoracic Surgery: A Case Report. *World J Surg Surgical Res.* 2019; 2: 1161.

Copyright © 2019 Gregory D Trachiotis and Eric R Heinz. This is an open access article distributed under the Creative Commons Attribution License, which permits unrestricted use, distribution, and reproduction in any medium, provided the original work is properly cited.

Introduction

Angiotensin II is a naturally secreted peptide hormone that plays a significant role in the renin-angiotensin-aldosterone system (Figure 1), and its physiological effect, through multiple mechanisms, is to increase blood pressure [1-4]. Angiotensin II causes direct arterial and venous smooth muscle vasoconstriction, modulates the effects of other catecholamines, and stimulates the secretion of aldosterone and antidiuretic hormones to promote sodium retention and water reabsorption. It is initially secreted as a prohormone, angiotensinogen, in the liver.

Angiotensinogen is cleaved by the enzyme renin, which is secreted by the kidney, into angiotensin I, and then cleaved into angiotensin II by angiotensin converting enzyme in the lungs [1,2,4].

An exogenous form of angiotensin II under the trade name Giapreza was approved by the Food and Drug Administration for medical use to treat hypotension in adults with septic or distributive shock [6]. Angiotensin II has been studied and used for patients with vasodilatory shock refractory to catecholaminergic vasopressors [1-3]. More recently, its catecholamine-sparing effect as a vasopressor has sparked significant clinical interest [3]. Here, we present a case in which angiotensin II was used for its catecholamine-sparing effect as a vasopressor in a Jehovah's Witness patient who developed vasodilatory shock during right-sided video-assisted thoracoscopic decortication of an empyema. Written Health Insurance Portability and Accountability Act authorization was obtained from the patient and all patient identifiers were removed from this case report.

Case Presentation

An 80-year-old woman of the Jehovah's witness faith with a history of diabetes, hypertension, and prior myocardial infarction with resultant placement of two coronary stents underwent an elective robotic-assisted epiphrenic esophageal diverticulectomy and myotomy. She tolerated the procedure well with an uneventful perioperative course. She was discharged to a sub-acute rehabilitation center on postoperative day four. A week following discharge, she presented to an outside hospital with abdominal pain, vomiting, constipation, and leukocytosis of $39 \times 10^3/\mu\text{L}$; she was diagnosed with a small bowel volvulus and a large, right-sided, loculated pleural effusion. She underwent emergent exploratory laparotomy, lysis of adhesions and detorsion of a small bowel volvulus without the need for bowel resection. Post-operatively she remained intubated. Subsequently, a right-sided thoracentesis was performed to drain the pleural effusion. The thoracentesis fluid analysis was consistent with an empyema. Despite resolution of her small bowel volvulus and thoracentesis, she remained critically ill and was subsequently transferred to our hospital's intensive care unit for further management. Upon arrival to our institution, the patient

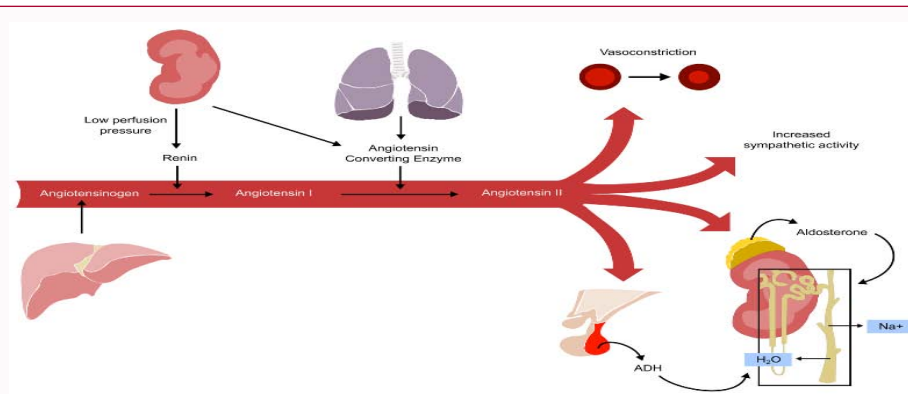


Figure 1: Renin Angiotensin Aldosterone System Pathway.

remained intubated with no vasopressor requirement. Her labs were notable for a leukocytosis of $19 \times 10^3/\mu\text{L}$ and hemoglobin of 6.9 gm/dL. In the context of failed thoracentesis and antibiotic therapy, the patient was scheduled for an urgent, right-sided video-assisted thoracoscopic decortication the day after arrival. During her prior procedures, and prior to intubation, the patient had made her wishes clear to decline blood product transfusion honoring her religious belief (patient was willing to receive albumin, but no other blood products or cell-salvage techniques). At the time of surgery, she was intubated and sedated, but hemodynamically stable. She was brought into the operating room from the intensive care unit with standard American Society of Anesthesiologists monitors. An arterial line was placed under ultrasound guidance. A 37 French double lumen tube was successfully exchanged through an endotracheal tub exchanger under direct laryngoscopy with a grade one view. The patient was then placed in left lateral decubitus position, and one-lung ventilation commenced. Subsequent to airway management, line placement, and positioning, the thoracic surgery team proceeded with a right-sided thoracoscopic decortication. Approximately 45 minutes into the case, the patient became acutely hypoxic and hypotensive with a Mean Arterial Pressure (MAP) decrease from 70s to 50s. The patient's oxygen saturation also improved after the removal of 1.8 liters of purulent fluid from her pleural space, but she remained hypotensive. She was started on angiotensin II at an infusion rate of 20 nanogram/kilogram/minute and albumin 12.5 grams was administered, after which, her blood pressure stabilized with her MAP remaining in the 70s to 80s. Fifteen minutes after initiating angiotensin II, the patient was weaned off the vasopressor. She remained hemodynamically stable throughout the remainder of the procedure. At the end of the case, the double lumen tube was exchanged over an endotracheal tube exchanger for a 7.5 endotracheal tube. The patient remained intubated and was transferred uneventfully to the intensive care unit. She was extubated on postoperative day two. Several days later, on postoperative day seven, the patient developed respiratory distress with an increase in oxygen requirement. Repeat imaging showed re-accumulation of the pleural effusion. At this point, the 7 patient's family decided to forego invasive procedures and prioritize comfort measures. She was discharged to an inpatient hospice near her family on postoperative day eighteen.

Discussion

Vasodilatory shock, also known as distributive shock is a form of circulatory shock that accounts for approximately two-thirds of reported cases. Septic shock is a subset of vasodilatory shock. It is

a life-threatening condition characterized by hypotension, tissue hypoperfusion, and poor oxygen utilization, all contributing to multi-system organ failure and death [1-4]. The standard management of shock is to maintain a specific blood pressure goal to prevent tissue hypoperfusion by means of fluid resuscitation and utilization of vasopressors [1-5]. Traditionally, first line vasopressors include catecholaminergic agents, such as norepinephrine and epinephrine, and vasopressin [1-5]. Depending on the level of vasoplegia and vascular responsiveness, large doses may be required to achieve blood pressure goals. The dose of vasopressors required to maintain a MAP goal can put patients at risk for adverse events, such as dysrhythmias, organ dysfunction, and worsening of peripheral and splanchnic ischemia [3,6]. Although studied, no specific vasopressor has been shown to outperform any other with respect to mortality rates in critically ill patients [3]. Since its discovery in the 1930's, angiotensin II has been used and studied clinically and experimentally [3]. The recent release of Giapreza coupled with the Angiotensin II for the Treatment of High-Output Shock-3 trial increased interest in using angiotensin II to treat shock [1-6]. Our patient's multiple comorbidities made her a poor candidate for fluid resuscitation or catecholaminergic pressure support. Her starting hemoglobin was 6.9 gm/dL, and further volume resuscitation would have worsened the anemia *via* hemodilution. Her cardiac history and critical illness increased her risk for an adverse cardiac event, which catecholaminergic vasopressors may have further provoked [7]. Intraoperative hypotension was only transiently resolved with phenylephrine. Consequently, we initiated angiotensin II, which was ordered from pharmacy ahead of time and brought in with the patient to the operating room, as the next vasopressor. We started the patient on the lowest dose recommended at 20 nanogram/kilogram/minute and saw an increase in systolic blood pressure to the 100s to 110s and MAP to 70s-80s within the next minute. No other surgical rationale could account for the improvement in blood pressure; the empyema was already drained prior to initiation of angiotensin II and there was no evidence of major vessel compression during the case. In previous studies, angiotensin II is used in conjunction with other vasopressors. It has been used as a last line therapy to raise blood pressure in patient's already on high doses of catecholaminergic agents and also used to help wean off other vasopressors [2-5]. The use of angiotensin II as the sole vasopressor, as in our case, has yet to be reported; further, there have been no studies evaluating the efficacy of angiotensin II as a monotherapy. The Angiotensin II for the Treatment of High-Output Shock-3 trial showed angiotensin II significantly increased blood pressure in patients with vasodilatory shock, with a subsequent

decrease in catecholaminergic vasopressor requirements. The study reported non-inferiority with respect to mortality rate or adverse cardiac events compared to saline placebo. Although more studies are required to evaluate angiotensin II, particularly as a monotherapy, its mechanism of action and catecholamine-sparing effects would make it a favorable vasopressor in vasodilatory shock patients, such as ours, who are at high risk for adverse effects from excessive fluids and catecholaminergic vasopressor therapy.

References

1. Khanna A, English SW, Wang XS, Ham K, Tumlin J, Szerlip H, et al. Angiotensin II for the Treatment of Vasodilatory Shock. *N Engl J Med.* 2017;377(5):419-30.
2. Bussard RL, Busse LW. Angiotensin II: a new therapeutic option for vasodilatory shock. *Ther Clin Risk Manag.* 2018;14:1287-98.
3. Busse L, McCurdy M, Ali O, Hall A, Chen H, Ostermann M, et al. The effect of angiotensin II on blood pressure in patients with circulatory shock: a structured review of the literature. *Crit Care.* 2017;21(1):324.
4. Chawla LS, Busse L, Brasha-Mitchell E, Davison D, Honiq J, Alotaibi Z, et al. Intravenous angiotensin II for the treatment of high-output shock (ATHOS trial): a pilot study. *Crit Care.* 2014;18(5):534.
5. Chow JH, Galvagno SM, Tanaka KA, Mazzeffi MA, Chancer Z, Henderson R, et al. When All Else Fails: Novel Use of Angiotensin II for Vasodilatory Shock. *A A Pract.* 2018;11(7):175-180.
6. Senatore F, Jagadeesh G, Rose M, Pillai VC, Hariharan S, Liu Q, et al. FDA Approval of Angiotensin II for the Treatment of Hypotension in Adults with Distributive Shock. *Am J Cardiovasc Drugs.* 2019;19(1):11-20.
7. Schmittinger CA, Torgersen C, Luckner G, Schröder DC, Lorenz I, Dünser MW, et al. Adverse cardiac events during catecholamine vasopressor therapy: a prospective observational study. *Intensive Care Med.* 2012;38(6):950-58.