



Pilonidal Disease Laser Therapy: Short Term Results of an Observational Cohort Study

Alferink M¹, Atmowihardjo L^{1*}, Smeenk R², Cadanova D¹ and Schouten R³

¹Department of Surgery, Dijklander Hospital, Netherlands

²Department of Surgery, Albert Schweitzer Hospital, Netherlands

³Department of Surgery, Flevo Hospital, Netherlands

Abstract

Background: Despite known complications and a high recurrence rate, the standard treatment of pilonidal disease still consists of surgical excision of the sinusoidal cyst with primary wound closure. We were the first in the Netherlands to introduce a new treatment technique using a radial laser probe (Sinus Laser-Assisted Closure, SiLaCTM, Biolitec, Germany). During this minimally invasive intervention, the radiation energy delivered via the laser probe obliterates the pilonidal cyst and sinus tract upon retraction of the device. Previous studies have shown encouraging results with respect to safety, patient satisfaction and minimal recurrence rates.

Method: We studied the data of our first 50 patients operated with this technique between February 2017 and December 2017 using a prospective database and digital questionnaires.

Results: The median follow up duration was 120 days. The initial success rate was 92% (45/50). There were no complications during or after surgery. Mean patient satisfaction was 9.0 (3.0 to 10.0). Thirteen percent of patients did not require any analgesia, 37% used only when needed, of which 32% for less than one week and 10% for one to two weeks.

Conclusion: SiLaC is a quick, safe and minimally invasive technique for destruction of the pilonidal cyst and sinus. Success rate and patient satisfaction are high, making this new therapy an attractive option for the majority of the patients with pilonidal disease. Long term results have to be awaited.

OPEN ACCESS

*Correspondence:

Leila Atmowihardjo, Department of Surgery, Dijklander Hospital, Hoorn, Weteringschans 273, 1017 XJ Amsterdam, Netherlands, E-mail: leila.atmowihardjo@gmail.com

Received Date: 20 Jun 2019

Accepted Date: 18 Jul 2019

Published Date: 23 Jul 2019

Citation:

Alferink M, Atmowihardjo L, Smeenk R, Cadanova D, Schouten R. Pilonidal Disease Laser Therapy: Short Term Results of an Observational Cohort Study. *World J Surg Surgical Res.* 2019; 2: 1143.

Copyright © 2019 Atmowihardjo

L. This is an open access article distributed under the Creative Commons Attribution License, which permits unrestricted use, distribution, and reproduction in any medium, provided the original work is properly cited.

Introduction

Pilonidal Disease (PD) is an infection of the hair follicle that can cause painful cysts and sinus formation. The most common place for PD to develop is the coccygeal region, leading to significant discomfort when sitting or wearing tight clothes. The incidence of PD is approximately 26 per 100.000 persons [1], the most affected group being young men [2,3]. Other risk factors include excessive body hair, obesity and a sedentary lifestyle [4].

The current treatment for symptomatic PD is surgical excision of the sinus and the cyst, so-called pilonidal cystectomy. Primary closure, with or without tissue transposition, or secondary open healing, are subsequently chosen based on the size, depth and location of the wound. Despite a variety of surgical techniques available to reduce recurrence rates, PD operations frequently present with complications such as delayed wound healing, infection and persistent pain and recurrences, often requiring re-interventions [5].

In order to decrease complications and recurrence rates after PD excision, it is desirable to use a less invasive technique that allows patients to recover more quickly and permanently. Our center is the first in the Netherlands to introduce a minimally invasive treatment with a radial laser probe, causing obliteration of sinus tracts. Previous studies examining the use of this laser technique to treat anal fistulas and pilonidal sinus disease have shown promising results [6,7]. To contribute to the evidence available on this relatively new intervention, this study aimed to investigate the safety, efficacy and patient satisfaction of SiLaC in a PD population in the Netherlands.

Material and Methods

Fifty patients were operated with the laser technique by two surgeons from February 2017 to December 2017. Informed consent was obtained from all patients. All patients above the age 16, who had been clinically diagnosed with primary or recurrent PD, were eligible for laser

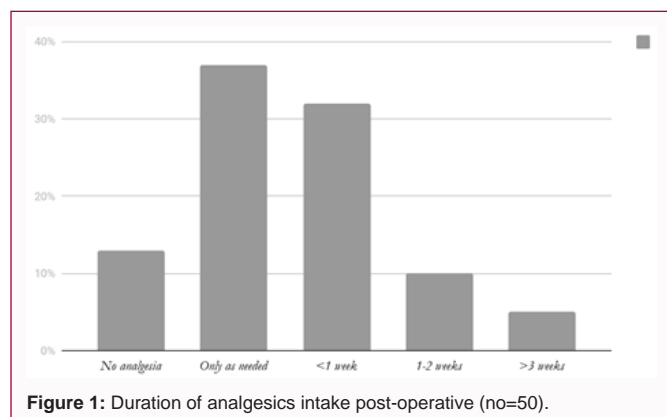


Figure 1: Duration of analgesics intake post-operative (no=50).

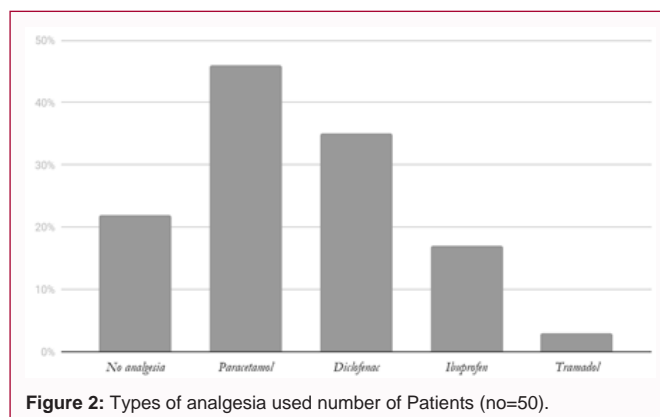


Figure 2: Types of analgesia used number of Patients (no=50).

intervention. There were no exclusion criteria among this patient group. All patients signed informed consent for the intervention and subsequent data collection.

We used a prospective database and self-developed digital questionnaire including patient demographics, postoperative complications, duration of pain evaluated by the use of analgesics, patient satisfaction, and duration of hospital stay, persistent open sinus and recurrence after healing (Addendum 1).

Technique

The operation is performed under locoregional or general anesthesia. Patients are placed in left-side position. After shaving, cleaning and scrubbing of the skin with alcoholic chlorhexidine, double strong tape is placed on the right buttock in order to increase exposure. Local anesthesia is administered before incision with 20 ml bupivacaine. The sinusoidal pits are enlarged with a biopsy core punch (4 mm, 6 mm or 8 mm depending on pit size). Hair and debris is removed from the sinus tracts with a small surgical spoon. Saline water is used for debris washout and ropivacaine is injected under the skin around the pits and in the tracts for tissue protective cooling. Subsequently, a radial diode laser probe at 1470 nm wavelength is used. The laser energy is 13 Joule. The radial fiber delivers energy homogeneously at 360 degrees. First, a preparatory laser treatment is performed, after which the sinus tracts are cleansed with a surgical spoon again. During the following definitive procedure, the probe is withdrawn at an approximate speed of 1 cm per two to three seconds, causing the small sinus tracts to shrink and close. If the tract is not closed after a first withdrawal, a second intervention is performed. Large sinus tracts remain open. The injury to the endothelium will cause granulation and subsequent closure. At the end of the procedure, a washout with saline is performed and sterile dressings are applied.

In the first postoperative period (two weeks), patients were advised to keep the puncture wounds open with a thin cotton swab to prevent premature closing of the skin and to use analgesia when necessary. One and three week's postoperative follow-up was conducted in all cases to evaluate pain medication, inspect and open the pits when necessary, and detect possible complications. After the first period, patients were seen six weeks and three months after the operation in order to evaluate wound healing and closure and to detect any persistent sinus activity or early recurrences. Digital questionnaires were obtained after two weeks (focusing on pain and use of analgesics), three months (focusing on wound healing and closing) and after one year (focusing on recurrences).

Statistics

Demographic data was presented using descriptive statistics in Microsoft Excel. Continuous variables were expressed as mean and Standard Deviation (SD), and median and Interquartile Range (IQR), respectively.

Results

The results show that after the first intervention, 90% of patients were successfully treated without requiring a re-laser or surgical excision. Five patients had persistent sinusoidal disease after laser intervention. In all of the persistent cases, there was one remaining sinus, while all other tracts were closed during the first laser treatment. These remaining sinuses were treated with either local excision (n=1) or re-laser treatment (n=4). After the second treatments, all sinuses were closed after a mean follow-up of 82 days (Table 1 and 2).

There were no cases of true recurrence after successful laser treatment. No cases of wound infection, bleeding complications or severe postoperative pain were reported.

According to the questionnaires, patient satisfaction was high. The median satisfaction score was 9.0 [3.0 to 10.0] on a scale 1 to 10, and patients reported little postoperative pain. Thirteen percent of patients did not require any analgesia, 37% only occasionally, 32% for less than 1 week, 10% for one to two weeks and after three weeks only 5% of patients still used analgesics (Figure 1). Paracetamol was most frequently used, followed by Non-Steroidal Anti-Inflammatory Drugs (NSAIDs). Three percent of patients used tramadol, however only in the first week after the intervention (Figure 2).

Discussion

This study reports the first short-term outcomes of an observational cohort of 50 patients with PD treated with SiLaC in the Netherlands. The aim of the present study was to examine the safety and efficacy of SiLaC and patient satisfaction.

The success rate of SiLaC was high regardless the number of prior operations, thereby indicating effectiveness in a diverse spectrum of PD history and morbidity. Also in patients that needed a re-laser or re-excision, SiLaC was shown to be an effective treatment. Moreover, patient satisfaction was high. So far, no disease recurrence has presented on short term follow-up. No complications were found during and/or after the treatment with the SiLac.

Before the onset of minimally invasive techniques such as Endoscopic Pilonidal Sinus (EPSiT) [7,8] and laser treatment, surgical excision was the standard intervention for PD. In simple

Table 1: Patient and operative characteristics.

Male: Female sex (%)	80:20:00
Mean age in years [range]	28.5 [15 to 57]
Median age in years [range]	24 [16 to 57]
Primary disease, n (%)	30 (60)
First recurrence	6 (12)
Second recurrence	5 (10)
Third recurrence	5 (10)
Fourth recurrence	2 (4)
Fifth recurrence	2 (4)
Mean follow-up duration in days [range] (n=50)	120 [60 to 420]
Mean follow-up after re-laser in days [range] (n=4)	82 [39 to 112]
Follow-up after excision in days (n=1)	39

Table 2: Results and complications (n=50).

Successful primary treatment* (%)	45/50 (90)
Success after re-laser or local excision (%)	5/5 (100)
Recurrence (%)	0/50 (0)
Complications** (%)	0/50(0)

*Defined as treatment not requiring re-laser or excision

**Defined as wound infection, bleeding or severe postoperative pain

cases, excision is followed by open healing or closing of the defect. Mean healing time after the open approach varies from one to three months [9-12], while direct suturing results in a quicker mean recovery time of two to four weeks [11,12]. Postoperative complications such as wound infection and dehiscence occur in up to 20% [11,12]. Recurrence rates after surgical excision range from 3% to 20% [10-13], depending on the severity of the preoperative presentation. In complex disease (i.e. multiple sinuses, long sinuses with multiple side tracts, abscess formation) more extensive surgical excision might be required. Techniques such as the V-Y advancement flap [12], rhomboid excision and Limberg flap [14,15], whole natal cleft excision or Z-plasty are used [16,17]. Not surprisingly, morbidity is considerably higher in this group [15]. Therefore, this complex patient group has the biggest potential benefit from SiLaC.

The population at risk mostly consists of young individuals who either attend school or are employed. To allow for a swift and permanent recovery of these patients, as well as those suffering from extensive PD, a better and less invasive technique is necessary. As a result, more research of laser therapy has recently been conducted. Pappas et al. [18] showed a success rate of 90.3% (214/237) after the first laser treatment. The patients who needed a second treatment had a success rate of 78.3% (18/23). They described different stages of complexity of PD. The most impressive results were obtained in the complicated cases, in which the main sinus was longer and had multiple side tracts. They also included relapsing disease after one or more previous incisions performed elsewhere. The success rate of these complicates cases was 100% (27/27), with no recurrences after a median follow-up of 354 days [range 240 days to 390 days]. These promising results correspond to our findings in complex cases. Despite 20 patients with previously recurrent disease (one to five recurrences), only five cases required re-laser or excision after their first SiLaC treatment. All five cases were successfully treated in one extra re-intervention session.

Another study about the laser technique was conducted by

Dessily et al. [6]. Their results showed a success rate of 87% (35/40) after the first laser treatment. The complication rate was 10% (4/40). Complications that occurred were two hematomas and two abscesses, which were all medically treated. Contrary to these findings, our patient population had no complications.

Besides the laser technique, another minimally invasive method described by Meneiro et al. [7], is called Endoscopic Pilonidal Sinus Treatment (EPSiT). This technique involves an endoscopic fistuloscope that is introduced into the sinus under spinal anesthesia. Granulation tissue, necrosis and hairs are removed under direct vision. A strong aspect of this technique is that it provides a good clearance of the cavity for the surgeon. It also causes a widening of the external opening following optimal wound drainage and secondary healing. The success rate was 94.8% (237/250). Persistent or recurrent PD was treated with a re-EPSiT with a success rate of 100% (21/21). The recurrence rate was low 5% (12/237) after a complete healing (>4 months) with a mean follow-up time of 12 months. Considering the promising results of EPSiT, it is appropriate to question the added benefit of using laser technology. It is plausible that during SiLaC treatment, extra hair and debris gets mobilized from the pit by means of sticking to the radial probe.

Limitations and Future Perspective

This observational cohort study adds to our understanding of the safety, efficacy and patient satisfaction of SiLaC treatment for PD. However, a major limitation of this study is the small sample size of fifty patients. A larger sample size is needed in future research to achieve a more representative population. Another limitation is the relatively short median follow-up duration of four months. Additionally, recall bias might have affected the results. A prospective (randomized) study with longer median follow-up is required to establish recurrence rates more accurately.

A natural progression of this study is therefore to analyze long-term follow-up data of recurrence. We designed a prospective study that consists of a larger patient population. It uses three digital questionnaires that require patients to answer sets of questions at two weeks, three months and one year. Results are not yet available.

To provide the highest level of evidence, future research will consist of a large multicenter randomized-controlled trial to directly compare SiLaC with surgical excision for treatment of sinus pilonidal disease. To investigate the added benefit of laser technology to pit-picking alone, possibly with or without phenol treatment, a future randomized-controlled trial that compares the two or three is warranted.

Conclusion

To conclude, SiLaC is a quick, safe and minimally invasive intervention to successfully treat primary and recurrent PD. This short-term observational cohort study indicated superiority of the laser technique in comparison with the current standard surgical excision to reduce postoperative pain, wound complications and short-term recurrence. Long-term follow-up of recurrence rates in a larger patient cohort is not yet available; however a prospective cohort study is currently ongoing.

References

1. Søndena K, Andersen E, Nesvik I, Søreide J. Patient characteristics and symptoms in chronic pilonidal sinus disease. *Int J Colorectal Dis.* 1995;10(1):39-42.

2. Doody DP, Pilonidal cyst disease. In: Mattei P, editor. *Fundamentals of pediatric surgery*. New York (NY): Springer Science & Business Media, LLC. 2011:467-74.
3. Enriquez-Navascues JM, Emparanza JI, Alkorta M, Placer C. Meta-analysis of randomized controlled trials comparing different techniques with primary closure for chronic pilonidal sinus. *Tech Coloproctol*. 2014;18(10):863-72.
4. Özdemir H, Ünal Özdemir Z, Tayfun Şahiner I, Şenol M. Whole natal cleft excision and flap: an alternative surgical method in extensive sacrococcygeal pilonidal sinus disease. *Acta Chir Belg*. 2014;114(4):266-70.
5. Al-Khamis A, McCallum I, King PM, Bruce J. Healing by primary versus secondary intention after surgical treatment for pilonidal sinus. *Cochrane Database Syst Rev*. 2010;CD006213.
6. Dessily M, Charara F, Ralea S, Allé JL. Pilonidal sinus destruction with a radial laser probe: technique and first Belgian experience. *Acta Chirurgica Belgica*. 2017;117(3):164-8.
7. Meinero P, Stazi A, Carbone A, Fasolini F, Regusci L, La Torre M. Endoscopic pilonidal sinus treatment: a prospective multicentre trial. *Colorectal Dis*. 2016;18(5):164-70.
8. Meinero P, Mori L, Gasloli G. Endoscopic pilonidal sinus treatment (E.P.Si.T.). *Tech Coloproctol*. 2014;18(4):389-92.
9. Jensen SL, Harling H. Prognosis after simple incision and drainage for a first-episode acute pilonidal abscess. *Br J Surg*. 1988;75(1):60-1.
10. Testini M, Piccinni G, Miniello S, Di Venere B, Lissidini G, Nicolardi V, et al. Treatment of chronic pilonidal sinus with local anaesthesia: a randomized trial of closed compared with open technique. *Colorectal Dis* 2001;3(6):427-30.
11. Kamran H, Ahmed A, Ali Khan I, Khan R, Asad S, Khattak I. Pilonidal Sinus: A Comparative Study of Open Versus Closed Methods of Surgical Approach. *JIIIMC* 2017;12(2):111-5.
12. Sahasrabudhe P, Panse N, Waghmare C, Waykole P. V-Y advancement flap technique in resurfacing postexcisional defect in cases with pilonidal sinus disease-study of 25 cases. *Indian J Surg*. 2012;74(5):364-70.
13. Gencosmanoglu R, Inceoglu R. Modified lay-open (incision, curettage, partial lateral wall excision and marsupialization) versus total excision with primary closure in the treatment of chronic sacrococcygeal pilonidal sinus: a prospective, randomized clinical trial with a complete two-year follow-up. *Int J Colorectal Dis*. 2005;20(5):415-22.
14. Yabanoglu H, Karagulle E, Belli S, Turk E. Results of modified Dufourmentel Rhomboid flap in patients with extensive sacrococcygeal pilonidal disease. *Acta Chir Belg*. 2014;114(1):52-7.
15. Karakayali F, Karagulle E, Karabulut Z, Oksuz E, Moray G, Haberal M. Unroofing and marsupialization vs. rhomboid excision and Limberg flap in pilonidal disease: a prospective, randomized, clinical trial. *Dis Colon Rectum*. 2009;52(3):496-502.
16. Özdemir H, Ünal Özdemir Z, Tayfun Şahiner I, Şenol M. Whole natal cleft excision and flap: an alternative surgical method in extensive sacrococcygeal pilonidal sinus disease. *Acta Chir Belg*. 2014;114(4):266-70.
17. Monro RS, McDermott FT. The elimination of causal factors in pilonidal sinus treated by z-plasty. *Br J Surg*. 1965;52:177-81.
18. Pappas AF, Christodoulou DK. A new minimally invasive treatment of pilonidal sinus disease with the use of a diode laser: a prospective large series of patients. *Colorectal Dis*. 2018;20(8):207-14.