World Journal of Surgery and Surgical Research

Case Series
Published: 19 Nov, 2020

The "Double" Diagnostic Delay in Crohn's Disease during the COVID-19 Pandemic

Denise Gambardella[1], Luigino Borrello[1], Basilio Caparello[1], Aldo Schicchi[1], Gianlorenzo Dionigi[2], Ettore Caruso[2]* and Manfredo Tedesco[1]

[1]Department of General Surgery, "G. Paolo II Hospital", University of Catanzaro, Italy

[2]Division of Endocrine and Minimally Invasive Surgery, University of Messina, Italy

Abstract

With the advent of the COVID-19 pandemic, greater attention was paid to all frail patients including those with IBD. The overall available evidence suggests that IBD patients do not have an increased risk of developing COVID-19 and should stay on IBD medications. COVID-19 pandemic has rapidly spread in Italy in late February 2020. Almost all surgical services have been reorganized, with the aim of maintaining an adequate therapeutic path, especially for surgical emergencies. A reduction in surgical emergencies has certainly been documented but not in their severity. This is because in "COVID era" patients are still afraid to go to the hospital even in the presence of severe symptoms. We describe a series of cases of severe presentation of Crohn's disease treated between April and May 2020 with perforating and/or bowel obstruction.

Introduction

Crohn's disease is a chronic inflammatory condition that affects the entire gastrointestinal tract from mouth to anus accompanied by various complications, including extra gastrointestinal ones [1]. The risk that a patient with Crohn undergoes surgery is 60% to 80% [2-3], with a significantly increased risk especially in the first few years following diagnosis [2]. Surgery is usually required for the presence of fistulas, abscesses, perianal disease, medically resistant disease, perforation, obstruction, strictures, uncontrolled bleeding. These patients have an increased risk of dysplasia, and malignancy which also lead to surgery. Certainly, to prevent the recurrence of surgery, adequate therapy is necessary [1-2].

During the pandemic the reference centers for care of IBD had to be reorganized to allow adequate assistance to these patients. The outbreak of the new coronavirus (SARS-CoV-2) officially named SARS-CoV-2, which causes COVID-19, is rapidly spreading worldwide [1] and Italy is the most affected country in Europe [4-5]. More attention has been paid to frail patients more susceptible to developing fatal complications from COVID-19 infection. Among these, IBD patients have aroused much interest. Several studies have been performed to evaluate whether IBD patients had a greater susceptibility to COVID-19. There are several reasons why IBD patients were thought to be most susceptible to COVID-19 infection including the higher expression of ACE2 in Crohn's Disease (CD) than in Ulcerative Colitis [UC].

The ACE2 receptor is essential for promoting infection in the host. This receptor is present on cell membranes. There are several theories regarding the mode of infection in patients with IBD: One is that patient with IBD have increased the soluble form of ACE2 that act as a competitive interceptor of SARS-CoV-2, on the other the therapies to which patients with IBD are subjected include immune suppressors that make them fragile and susceptible to infections also for the suppression of the effector cytokine driven-inflammatory response. The overall available evidence suggests that IBD patients do not have an increased risk of developing COVID-19 and should stay on IBD medications 3) and must follow the same recommendations as the general population, i.e. practice strict social distancing, work from home, have meticulous hand hygiene, and separate themselves from known infected individuals [5,6].

Patients with IBD undergoing therapy should be carefully monitored like the rest of the population. In general, the phenotype of patients who are more susceptible to developing potentially fatal COVID-19-induced pneumonia, i.e. patients over 60 years and/or with comorbidities as coronary heart disease, hypertension, diabetes mellitus, lung disease, cerebrovascular diseases, have been identified. IBD patients should not leave therapies but continue to maintain remission and

OPEN ACCESS

Correspondence:
Ettore Caruso, Division of Endocrine and Minimally Invasive Surgery, University of Messina, Italy, E-mail: ettore_caruso@hotmail.it

Received Date: *15 Oct 2020*
Accepted Date*: 16 Nov 2020*
Published Date*: 19 Nov 2020*

Citation:
Gambardella D, Borrello L, Caparello B, Schicchi A, Dionigi G, Caruso E, et al. The "Double" Diagnostic Delay in Crohn's Disease during the COVID-19 Pandemic. World J Surg Surgical Res. 2020; 3: 1260.

avoid obvious negative consequences of a relapse, the need of steroid therapy, or necessitate hospitalization [5,6].

And Patients Who Don't Know They Have IBD?

The diagnosis of Crohn's Disease (CD) can be delayed in clinical practice. The symptoms may be mild and nonspecific for many years. The natural history of CD suggests increased incidence of complications with increasing duration. To this difficulty of CD diagnosis, we add the psychological impact of the outbreak in patients with severe abdominal symptoms who do not go to hospital for fear. COVID-19 outbreak is dramatically changing the practice of emergency surgery centers in Italy. Despite the reduction in number, urgent cases were on average more challenging owing to diagnostic delay [7]. We describe a series of cases of severe presentation of Crohn's disease treated between April and May 2020 with perforating and/or bowel obstruction in patient with diagnosis delay.

Case Series

Case Report 1

In April 2020, a 39-year-old male presented in our surgical department with fever, abdominal pain, diarrhea and weight loss. His medical history revealed hypertension and intestinal disorders since he was 20-years-old. He hasn't diagnosis of Crohn's disease. The patient reported having noticed a worsening of symptoms in the last month, and the onset of pain for about two days before going to the hospital. Routine blood, routine urine, blood biochemical tests were abnormal with white blood cell count was 22,000/μL and his C-reactive protein level 25 mg/d. During his admission in our department, the patient was subjected to CT with contrast the highlighted a parietal thickening of the last ileal loop with edema determining the narrowing of the lumen extended for 25 cm, perforation covered, increase in the size of the lymph nodes (Figure 1). This image initially posed for chronic inflammatory bowel disease in the active phase. Under these circumstances, the surgery recommended was a right hemicolectomy with associated terminal ileal resection along with resection of the sigmoid colon due to the presence of the ileosigmoid fistula. Several bowel stenoses have been observed intraoperatively. Post-operative course was uneventful. The patient recovered well and was discharged seven days after his operation. The diagnosis of CD was made histologically on the operating piece (Figure 2).

Case Report 2

A case is reported of innocuous intestinal obstruction requiring surgical intervention that was confirmed to be Crohn's disease histopathologically in a 70-year female with history of crampy lower-quadrant abdominal pain, non-bloody, non-mucoid diarrhea alternating with constipation presented to our surgical department

Figure 1: Preoperative CT scan.

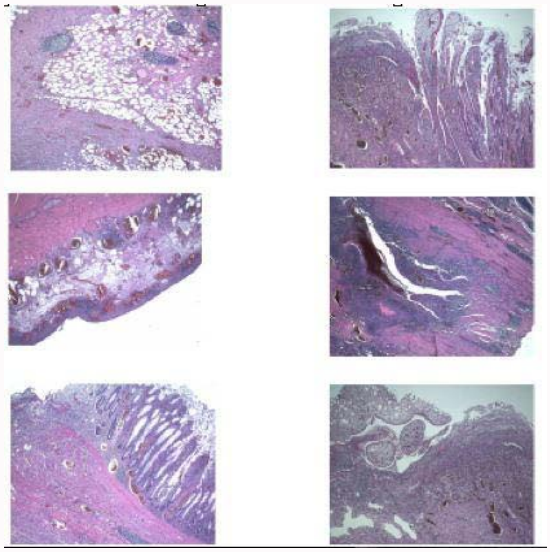

Figure 2: Histological detail with follicular morphology of inflammation, ganglionic hyperplasia, vascular congestion, superficial ulcers, pseudopolipoid aspects, parietal fissure.

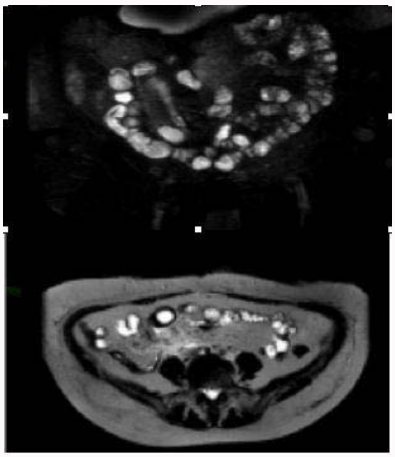

Figure 3a, 3b: Preoperative entero-RM.

abdominal examination of the patient revealed an ill-defined mass in the central quadrant and visible peristalsis. She also reported that he had noticed a worsening of symptoms for about 20 days with the presence of vomiting for about 5 days. The abdominal computed tomographic scan was negative for bowel obstruction. The patient underwent RMN which detected the marked contrast between the lumen and the dark bowel wall on T2-weighted images ameliorates the detection of intraluminal abnormalities and more effectively highlights transmural ulceration (Figure 3a,3b). The patient underwent exploratory laparotomy. The intraoperative finding was a multiple bowel's stenosis extended about 30 cm. She subsequently had ileal resection with latero-lateral anastomosis. The histopathological diagnosis confirmed Crohn's disease (Figure 4).

Case Report 3

A 51-year old female with a familiar history of Crohn's disease comes to our observation with symptoms of bowel obstruction. The patient reported having symptoms such as fever and diarrhea during the previous two months but the attending family medicine physician had advised against going to the hospital. On physical examination

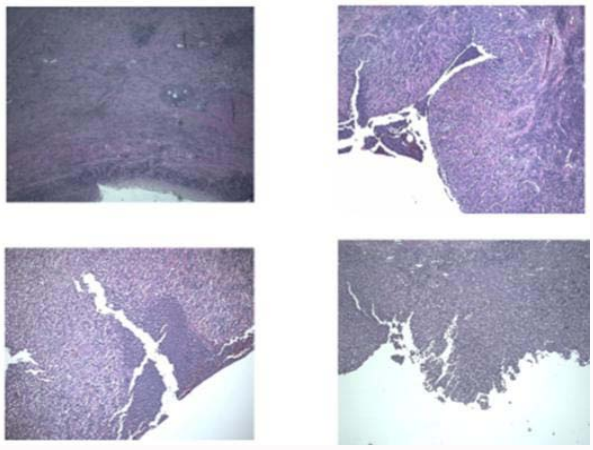

Figure 4: Ileus with diffusely ulcerated mucosa; perpendicular fissures in the submucosa; pseudopolipoid features of the mucosa with rich vascularization and lymphoplasmacellular infiltrate.

that had a temperature of 37.9°C, a pulse rate of 85 beats per minute, and a blood pressure of 125/72 mmHg. Her laboratory results showed leukocytosis (17,000/mm^3). She performed a CT scan which highlighted the presence of microbubbles in the small intestine. The patient underwent exploratory laparotomy. The intraoperative finding was a single bowel's stenosis extended about 10 cm on the last ileal loop She subsequently had ileal resection with ileo-colic latero-lateral anastomosis. The histopathological diagnosis confirmed Crohn's disease.

Discussion and Conclusion

Crohn's disease is an idiopathic disorder of the gastrointestinal tract, characterized by chronic, segmental inflammation, which typically has a relapsing and remitting course. Despite the use of immunosuppressive maintenance therapies, subclinical transmural inflammation persists in many patients, which predisposes them to such complications as strictures and fistulas [2]. We present three cases of Crohn's disease diagnosed histologically during the COVID-19 pandemic. In all three cases the patients waited before going to the hospital and had severe abdominal symptoms. The diagnostic delay for fear of hospitalization was on average 72, 5 days from the onset of abdominal symptoms. None of the three patients knew they had crohns. The first patients had signs of generalized peritonism and sepsis, the second patient showed advanced bowel occlusion. The diagnosis of Crohn's Disease (CD) may be difficult because the symptoms may be mild and nonspecific for many years. The greater diagnostic delay, the greater risk of complications and need for surgery. The cumulative risk of developing either stricturing or penetrating complication has ranged from 60% to as high as 88%. Diagnostic delay in CD is associated with significantly higher stenotic complications and need for surgery. There is no gold standard diagnostic test [8]. Ileocolonoscopy is the current gold standard reference for CD and is accurate for assessing mucosal abnormalities but it is invasive, carries a risk of bowel perforation, is incapable of assessing trans- and extramural disease, and is limited to the evaluation of the colon and terminal ileum only. We can study small bowel CD with Tomographic techniques, such as ultrasound, Magnetic Resonance (MR) and Computed Tomography (CT), allow evaluation of thickness and structural characteristics, and adjacent structures including the mesentery, fibrofatty tissue, lymph nodes, and the peritoneal spaces [9]. At the difficult diagnosis and diagnostic delay are added the problems related to the spread of the pandemic by COVID-19. Several studies have shown the impact of the pandemic on mental health and on the onset of anxiety. Also patients with severe abdominal symptoms are still afraid to go to hospitals because they were considered as places of infection source [10]. The pandemic has largely affected surgical activities. This survey, [7] focused on urgent interventions, showed a decline in the overall number of urgent cases, but associated with a more severe presentation due to diagnostic delay. All patients with fever, without respiratory symptoms were advised not to go to hospital. However, fever could be a manifestation of abdominal disease. Many interventions, both urgent and non-urgent, were not performed with considerable delay and with the risk of overloading the intensive care units and surgical wards already crowded in the following months.

In conclusion, it is difficult to diagnose Crohn's disease but we believe that the COVID-19 pandemic has aggravated the diagnostic delay that already characterizes this type of disease.

References

1. Veauthier B, Hornecker JR. Crohn's Disease: Diagnosis and Management. Am Fam Physician. 2018;98(11):661-9.
2. Guizzetti L, Zou G, Khanna R, Dulai PS, Sandborn WJ, Jairath V, et al. Development of clinical prediction models for surgery and complications in Crohn's Disease. J Crohns Colitis. 2018;12(2):167-77.
3. Monteleone G, Ardizzone S. Are patients with inflammatory bowel disease at increased risk for COVID-19 Infection? J Crohns Colitis. 2020;14(9):1334-6.
4. Fiorino G, Allocca M, Danese S, Gilardi D, Zilli A, Radice S, et al. Inflammatory bowel Disease Care in the COVID-19 Pandemic Era: The Humanitas, Milan, Experience. J Crohns Colitis. 2020;14(9):1330-3.
5. Danese S, Cecconi M, Spinelli A. Management of IBD during the COVID-19 outbreak: Resetting clinical priorities. Nat Rev Gastroenterol Hepatol. 2020;17(5):253-5.
6. Rubin DT, Feuerstein JD, Wang AY, Cohen RD. AGA clinical practice update on management of inflammatory bowel disease during the COVID-19 pandemic: Expert commentary. Gastroenterology. 2020;159(1):350-57.
7. Patriti A, Baiocchi GL, Catena F, Marini P, Catarci M, ACOI, et al. Emergency general surgery in Italy during the COVID-19 outbreak: First survey from the real life. World J Emerg Surg. 2020;15(1):36.
8. Banerjee R, Pal P, Girish BG, Reddy DN. Risk factors for diagnostic delay in Crohn's disease and their impact on long term complications: How do they differ in a tuberculosis endemic region? Aliment Pharmacol Ther. 2018;47(10):1367-74.
9. Minordi LM, Larosa L, Papa A, Bordonaro V, Lopetuso L, Holleran G, et al. Assessment of Crohn's disease activity: Magnetic resonance enterography in comparison with clinical and endoscopic evaluations. J Gastrointestin Liver Dis. 2019;28:213-24.
10. Sher L. COVID-19, anxiety, sleep disturbances and suicide. Sleep Med. 2020;70:124.