World Journal of Surgery and Surgical Research

Research Article
Published: 10 Feb, 2020

# Spinal Instability following Multilevel Decompressive Laminectomy without Fusion for Degenerative Lumbar Canal Stenosis

*Thamer A Hamdan and Ahmad S Abdul Hassan**

*Department of Orthopedic and Spine Surgery, University of Basrah, Iraq*

## Abstract

**Purpose:** This study explores segmental instability as a possible complication of decompressive laminectomy for lumbar spinal stenosis in terms of its occurrence and its impact on functional outcomes.

**Methods:** From March 2017 to March 2019, a prospective cohort study was conducted in Basrah Teaching Hospital, enrolled 25 patients with degenerative lumbar canal stenosis without instability, who underwent first-time multilevel decompressive laminectomy preserving both facets , intervertebral discs and without fusion. They were followed up for a mean of 13 months (4-24); every patient was evaluated clinically and radiologically utilizing functional radiography to assess for segmental instability. Oswestry Disability Index (ODI) was used to determine the functional outcomes as well. Statistical analysis contemplated to explore any significant association between instability and the following patient characteristics: age, gender, body mass index, the pre-operative duration of complains diabetes mellitus and hypertension, total levels decompressed, and level of decompression. The analysis was repeated for any association between ODI and instability or the factors above.

**Results:** There was high prevalence of medical and other musculoskeletal comorbidity, the incidence of post-operative instability was 8%, No significant correlation was measured between the instability or ODI and patient characteristics.

**Conclusion:** On short and medium term follow up, facet preserving multilevel decompressive laminectomy is a rational treatment strategy providing pain relief and good functional outcomes for wide range of patients with degenerative spinal stenosis and no instability, as well as minimizing risks of spinal fusion, the indications of fusion should be restricted to patients of lumbar stenosis accompanied by spinal instability or deformity. Long term follow up is required to validate these results further.

**Keywords: Segmental instability; Spinal stenosis; Facet sparing laminectomy; Spinal fusion**

**OPEN ACCESS**

***Correspondence:***
*Ahmad S Abdul Hassan, Department of Orthopedic and Spine Surgery, University of Basrah, Basrah Medical College, PO Box: 1464, Basrah, Iraq, E-mail: hmdshihab@gmail.com*

**Received Date**: *01 Dec 2019*
**Accepted Date***: 04 Feb 2020*
**Published Date***: 10 Feb 2020*

***Citation:***
*Hamdan TA, Abdul Hassan AS. Spinal Instability following Multilevel Decompressive Laminectomy without Fusion for Degenerative Lumbar Canal Stenosis. World J Surg Surgical Res. 2020; 3: 1193.*



## Introduction

The lumbar spine copes for a unique functional demand for mobility in different planes along with load bearing capacity and the stability required to contain the neural structures, this is the result of specific mechanical characteristics of each individual spinal component as well as of the efficient integration of these components into the over-all structure of the spine [1]. Violation of this balanced structure during laminectomy may result in segmental instability of the lumbar spine. The development of post laminectomy instability can lead for persistent back pain or to recurrence of the stenosis leading to poor or unacceptable outcome that may require further surgical treatment.

Spinal stenosis is the most common indication for spinal surgery in people older than 65 years [2], for properly selected patients, decompressive surgery offers an advantage over conservative treatment [3-5]; therefore, it is important to choose the optimal method of treatment to suite the individual patient requirements and proper patient counseling. A study of the factors associated with the development of segmental instability and its correlation with patient outcomes could highlight the way how to avoid instability and when to recommend fusion.

## Patients and Methods

This prospective study was conducted in Basrah Teaching Hospital from March 2017 to March

2019, targeted patients with degenerative lumbar canal stenosis who failed to respond for conservative treatment and planned for first time multilevel lumbar decompression. Those with pre-existing instability as evidenced by lateral neutral, flexion and extension radiographs were excluded, as well as those who required single level decompression or concomitant discectomy or had intra-operative finding of instability prior to starting decompression.

### Operative technique

All surgeries were done by a single experienced surgeon to control for operative technique and extent of surgical resection. Clinical and radiographic findings dictated the levels that are most stenotic and symptoms generating and thence to be decompressed.

- The patient under general endotracheal anesthesia. In prone position using ordinary theatre table with pillows beneath the chest, pelvis and legs and free abdomen with single dose of pre-operative antibiotic.

- Utilizing the anatomical landmarks or C-arm (infrequently) for localization, an incision in the midline centered over the level of stenosis carried down to the fascia.

- Lumbar fascia incised or cauterized over spinous processes to just lateral of the midline. Sub-periosteal dissection with Cobb or chisel along spinous processes and lamina to reflect the paraspinal muscles to the level of facets.

- Spinous processes of the involved level are grasped with a holder or forceps and assessment for instability is made by applying transitional movements in the coronal and sagittal planes, this is judged by surgeon experience.

- Spinous processes of operative levels are removed with rongeur or bone cutter down to their bases along with the supraspinous and interspinous ligaments. The soft tissue cleared with a curette or bone nibbler.

- Starting from inter laminar space; parts of the lamina and ligamentum flavum are carefully resected with Kerrison rongeur. Portion of the lamina and the base of the spinous processes are spared so that these structures (in addition to the intact anterior structures) forms a bridge or a continuous ring that contribute for spinal stability (Figure 1). With further decompression made by undermining or undercutting beneath this bridge to remove the flavum.

- Decompression continue to identify the lateral margins of the dura in the lateral recesses with identification and probing of the exiting nerve roots to ensure the roots are freely mobile in the lateral recesses as well as in the exiting foramen with decompression extended accordingly, however; facets and pars are kept intact or only with limited resection of hypertrophied synovium or osteophytes.

- The operative field irrigated with normal saline, hemostasis secured and the wound closed in layers over a suction drain.

The patient is encouraged for mobilization in the first post-operative day and the drain is removed as well. The patient discharged home on the next day with an appointment for stitch removal after another ten days.

### Patient follow-up

During each follow up visit, history is taken to document degree of symptoms relief (backache, radicular pain, neurogenic claudication, paresthesia, weakness, and sphincter disturbances), with special consideration to some of the symptoms suggestive of instability. Physical examination of the lumbar spine and neurological examination of lower limbs performed along with special tests for lumbar instability. Oswestry Disability Index (ODI) was used to assess the functional level of each patient and to compare among different patients.

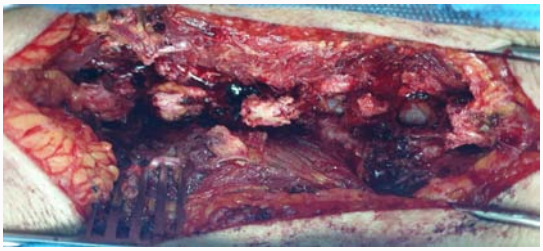

**Figure 1:** A photograph of the operative field, the blue arrows pointing at the dura after decompression, and the red arrows pointing at the remaining bases of the spinous processes and laminae.


**Figure 2:** Functional radiography in flexion (above) and in extension (below) with measurements for translation and angulation made using Surgimap software for analysis.

### Radiographic assessment

On follow up visit, functional radiography was used to assess for post laminectomy instability , the measurements were made using the Surgimap software version 2.2.15.5 according to the measurement technique and reference values described by Posner [6] (Table 1 and Figure 2 ). In order to minimize bias, measurements were made by two examiners (examiner A who is the researcher and examiner B who is a radiologist).

## Results

The mean follow up duration was 13 months (range 4 to 24 months), data collected from patients were analyzed using IBM SPSS

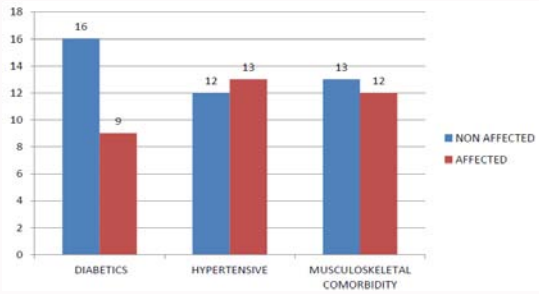


**Figure 3:** The distribution of comorbidity.

**Table 1:** Values for radiographic instability as described by Posner.

| Level | Anterior translation | Posterior translation | Angulation in flexion |
|---|---|---|---|
| L1 – L5 | More than 8% | More than 9% | More than -9 |
| L5 – S1 | More than 6% | | Less than 1 |

**Table 2:** Characteristics of patients involved in the study.

| Total number | 25 |
|---|---|
| Male/Female | 10/15 |
| Mean Age ± std. deviation | 60.75 ± 10.9 years |
| Mean duration of pre-operative complains | 19 ± 8.8 months |
| Diabetics | 9 (36%) |
| Hypertensive | 13 (52%) |
| Smokers | 1 (4%) |
| Mean BMI ± std. Deviation<br>Normal (18.5-25)<br>Overweight (25-30)<br>Obese (More than 30) | 29.8 ± 4.05 kg/m$^2$<br>1(4%)<br>14(56%)<br>10 (40 %) |
| Total Levels<br>2 level laminectomy<br>3 level laminectomy<br>L2-3<br>L3-4<br>L4-5<br>L5-S1 | 57<br>18/25 (72%)<br>7/25 (28 %)<br>8(14%)<br>23(41%) } 81%<br>23(41%)<br>3(5%) |

software version 22.

## Patients characteristics

A total of 40 patients were included initially, 11 patients did not attend for follow up, one case underwent revision in another institution without further details about the causes or nature of revision, one case had evidence of intraoperative instability and another 2 patients had concomitant discectomy, a net of 25 patients were enrolled in the study. Most of the sufferers of spinal stenosis in this study were females (15 out of 25), the mean age of presentation is 60.75 years (43 to 82, standard deviation =10.9 years) with an average duration of pre-operative complains about 19 months (range 6 to 40, standard deviation =8.8 months). For the 25 patients, 57 levels had been decompressed. Seven out of 25 patients (28%) patients had 3 level laminectomy (L2-3, L3-4 and L4-5), overall L3-4 and L4-5 were the levels most commonly affected by stenosis. Only 1 patient (4%) was smoker, none was alcoholic at the time of the study, most of the patients were overweight (mean body mass index =29.8 kg/m$^2$). High percentage of the patients (84%) had associated medical or other musculoskeletal (non-lumbar) comorbidities, 9 patients (36%) were diabetic and 13 patients (52%) were hypertensive. Table 2 summarizes patient characteristics and (Figure 3) demonstrates the distribution of comorbidities.

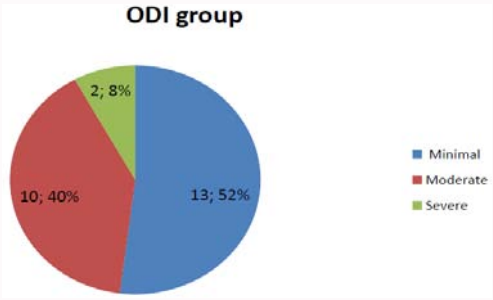


**Figure 4:** Distribution of ODI score.

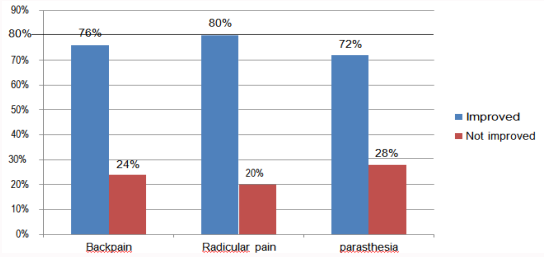


**Figure 5:** Improvement of the main presenting complains.

## Development of instability

According to the results of functional radiography, only 2 patients had segmental instability, this corresponds to 8% incidence of instability. The finding of instability for both cases was made after 18 and 16 months follow up period, however; there is no statistically significant correlation between development of instability and follow up period (p value =0.33 using the Pearson correlation test).

The first patient was a female, 71 years old, diabetic, obese (BMI =31 Kg/m$^2$), osteoporotic, grand multiparous (10 births), with more than 2 years of symptoms, had L2-3, L3-4 and L4-5 laminectomy, she had L2-3 instability seen as 17% posterior translation on functional radiography and her ODI at 18 months post operatively was 42% but she could cope for most household activities of daily living.

The other patient was a male, 75 years old, diabetic and hypertensive, overweight (BMI =29 Kg/m$^2$), with more than 2 years of symptoms, had L3-4 and L4-5 decompression and L3-4 instability (14% posterior translation), his ODI at 16 months post operatively was only 4% and he continue active life of a university professor.

Chi-squared test and significance level at (p value ≤ 0.05) used for statistical analysis for any significant association between development of instability and the factors listed in Table 3.

It seems that development of instability has no statistically significant association with each of the variables under analysis.

## Post-operative functional status

The results and distribution of patients according to the categories of ODI are presented in Table 4 and Figure 4.

Statistical analysis (using Chi-squared test and P value ≤ 0.05) is repeated for the association between ODI score and each of the clinical factors presented in Table 5, again the analysis discloses no significant association.

## Symptoms relief and complications

76% of patients reported relief of back pain, including 28% with

**Table 3:** Analysis of factors between stability and instability groups.

| Variable | | Instability group (n=2) | Stability group (n=23) | P value |
|---|---|---|---|---|
| Age | Below 65 | 0 | 16 | 0.12 |
| | Above 65 | 2 | 7 | |
| Gender | Male | 1 | 9 | 1 |
| | Female | 1 | 14 | |
| BMI | Normal | 0 | 1 | 0.92 |
| | Overweight | 1 | 13 | |
| | Obese | 1 | 9 | |
| Diabetes mellitus | YES | 2 | 7 | 0.12 |
| | NO | 0 | 16 | |
| Hypertension | YES | 1 | 12 | 0.74 |
| | NO | 1 | 11 | |
| Pre-operative pain | Up to 12 months | 0 | 9 | 0.52 |
| | More than 12 months | 2 | 14 | |
| No. of levels | 2 | 1 | 17 | 0.49 |
| | 3 | 1 | 6 | |
| Level of decompression | L2-3 | 7 | 1 | 0.35 |
| | L3-4 | 22 | 1 | |
| | L4-5 | 23 | 0 | |
| | L5-S1 | 3 | 0 | |

**Table 4:** Frequency table of the disability.

| | |
|---|---|
| Minimal disability | 13 (52%) |
| Moderate disability | 10 (40%) |
| Severe disability | 2 (8%) |

full pain relief and 48% with some improvement. In 24% of patients, the surgery did not relieve back pain or relieved only during the early post-operative months. Likewise, radicular pain and numbness improved in 80% and 72% of patients respectively, including 52% and 48% with full resolution of symptom. (Table 6 and Figure 5) represent these findings.

In two cases that had foot drop pre-operatively, the surgery only partially improved the condition at 12 months of follow up for the first case and at 18 months for the other. No other complications were reported.

## Discussion

Among all musculoskeletal conditions, low back pain is the single leading cause of disability globally [7]. Spinal stenosis in older patients is a common source of low back pain. Many of them fail to respond to conservative measures, thence indicated for decompressive laminectomy. Comorbidity is common in elderly patients, and usually their functional demands are not high, this should be considered when choosing the treatment strategy that must improves risk to benefit ratio.

In this context, decompressive laminectomy without supplemental fusion can provide rational surgical treatment for spinal stenosis without pre-operative instability as far as measures are taken to preserve this stability. Williams et al. [8] in a recent prospective study of 119 patients undergoing facet sparing laminectomy or laminotomy surgery for LSS, found that all patients reported improvement in back and leg pain and Oswestry disability index at 6 weeks and 1 year

**Table 5:** Statistical analysis of some clinical factors in association with ODI.

| Variable | | Instability group (n=2) | Stability group (n=23) | Severe | P value |
|---|---|---|---|---|---|
| Age | Below 65 | 10 | 6 | 0 | 0.15 |
| | Above 65 | 3 | 4 | 2 | |
| Gender | Male | 7 | 3 | 0 | 0.38 |
| | Female | 6 | 7 | 2 | |
| BMI | Normal | 1 | 0 | 0 | 0.3 |
| | Overweight | 5 | 8 | 1 | |
| | Obese | 7 | 2 | 1 | |
| Diabetes mellitus | YES | 4 | 3 | 2 | 0.23 |
| | NO | 9 | 7 | 0 | |
| Hypertension | YES | 6 | 6 | 1 | 0.83 |
| | NO | 7 | 4 | 1 | |
| Musculoskeletal comorbidity | YES | 5 | 5 | 2 | 0.31 |
| | NO | 8 | 5 | 0 | |
| Pre-operative pain | Up to 12 months | 6 | 3 | 0 | 0.57 |
| | More than 12 months | 7 | 7 | 2 | |
| No. of levels | 2 | 9 | 8 | 1 | 0.85 |
| | 3 | 4 | 2 | 1 | |
| Stability | unstable | 1 | 0 | 1 | 0.15 |
| | stable | 12 | 10 | 1 | |

**Table 6:** Improvement of Pain and Paresthesia.

| | Backache | Radicular pain | Numbness and paresthesia |
|---|---|---|---|
| Full relief | 7 (28%) | 13 (52%)* | 12 (48%)* |
| Improvement | 12 (48%) | 7 (28%) | 6 (24%) |
| Not improved | 6 (24%) | 5 (20%) | 7 (28%) |
| Total | 25 (100%) | 25 (100%) | 25 (100%) |

*Including those who are free of symptoms pre-operatively

follow up. This study did not involve assessment for post-operative instability or number of levels decompressed, however; 70% to 80% of the patients involved in our study reported improvement of symptoms.

BM Jolles et al. [9] in a retrospective review of patients with lumbar spinal stenosis who had been treated surgically and followed up for a mean of 6.5 years (5 to 8) after surgery have identified cohort of patients with lumbar stenosis without instability but develop progressive lumbar spinal instability, deformity, and/or spondylolisthesis post decompression. The incidence of this progressive slippage was 9%, this result is similar to our finding (8%) despite the variation in study designs and follow up protocols. M Fox et al. [10] evaluated clinical outcomes and radiological instability after 5.8 years (range 4.6 years to 6.8 years) following decompressive lumbar laminectomy for degenerative spinal stenosis, they reported progressive postoperative spondylolisthesis in 31% of patients with normal preoperative alignment (mean 7.8 mm, range 2 mm to 20 mm) and in 73% of patients with preoperative subluxation (mean 5.1 mm, range 2 mm to 13 mm) in whom fusion was not attained. Guha et al. [11] in a systematic literature review identified cohorts of patients with degenerative lumbar canal stenosis, either with or without preexisting spondylolisthesis, who were treated with laminectomy or minimally invasive decompression without fusion, they came to the conclusion that there was a higher incidence of post-

operative slippage among patients with preexisting spondylolisthesis (17%) *vs.* stenosis alone (5.3%, p<0.001) and among patients in whom open decompression was performed (13%) compared with minimally invasive technique (3.2%, p<0.001). There was a higher incidence of reoperation among patients with preexisting spondylolisthesis (8.9%) compared to those with stenosis alone (1.1%, p<0.001) and among patients in who open decompression was performed (11%) *vs.* a minimally invasive decompression (0.7%, p<0.001). It can be conclude that the reported incidence of post-operative instability is variable among the literature but depends largely on the preoperative radiographic findings and the extent of surgical decompression.

T Aalto et al. [12] in a prospective analysis for the pre-operative predictors for good post-operative outcomes in lumbar spinal stenosis surgery found that the age at time of surgery less than 75 years, regular pre-operative analgesic use for less than 12 months, no previous lumbar operation and non-smoking predicted good outcomes (95% CI=1.35-12.02; p=0.012, 95% CI=1.21-9.53; p=0.020 and 95% CI=1.13-11.79; p=0.031, 95% CI=1.09-11.03; p=0.035 respectively). Possible explanation for the correlation between outcomes and pre-operative complains is that longer duration of complains reflects more sustained compression of neural structures [13]. Our study did not disclose such correlation.

Instability after decompression does not predict poor results always [3], normal walking and ability to perform daily activities could improve regardless the instability, this is noticeable in our results that did not show any statistically significant correlation between post decompression stability status and ODI score (p=0.15). Similarly, long-term follow-up of Meyerding types III and IV of developmental spondylolisthesis (which is a frank form of instability) treated both operatively and non-operatively found that most patients had done relatively well. None had severe neurologic sequelae, and only 45% had even mild neurologic symptoms. At 18 year follow-up, 36% of patients treated non-operatively were asymptomatic [14]. RC Mulholland [15] in a review article claimed that abnormal movement of a degenerated segment may be associated with back pain but is not causative and the concept of instability as a cause of back pain is a myth, he emphasized the role of abnormal loading of the disc space as a pain generator.

Despite the numerous researches about the role of spinal fusion in surgery for spinal stenosis, it still represents one of the major controversial issues [4]. Established guidelines are generally in favor of concomitant fusion when the stenosis is associated with spondylolisthesis but not in the case of isolated spinal stenosis [16-18], mainly due to the added risks and comorbidity of fusion. Munting et al. [19] designed a multicenter study based on Spine Tango data registry to compare patient outcomes and complication rates after different decompression techniques or instrumented fusion in lumbar spinal stenosis, they concluded that better patient outcomes were obtained after laminectomy in combination with instrumented fusion, but they advised caution due to higher rates of surgical and general complications and consequent required measures.

Also, it should be kept in mind that attempt to fusion does not result in fusion always, in fact the rate of pseudoarthrosis can be comparable to the rate of instability itself or even higher. Bydon et al. [20] in a retrospective study of the impact of smoking on postoperative complications and pseudoarthrosis in adult patients undergoing posterolateral fusion of the lumbar spine, found that pseudoarthrosis occurred in 29.17% of smokers and in 10.92% of non-smokers followed up for an average of 53.5 months.

United States data show that the annual number of fusion operations has increased over 18 years (from 1993 to 2011) for about 600%. It is unlikely that the increment in the total number of unstable spines is the sole cause, but other possible factors may be responsible. Marketing of new surgical implants and products may be responsible also [21]. For instance, the introduction of interbody fusion cages accelerated fusion procedure rates. Jeffery as cited by Deyo [21] reports thirty millions dollar settlement to be paid by surgical implant manufacturers over alleged kickbacks to surgeons at 2012.

## Conclusion

On short and medium term follow up, facet preserving multilevel decompressive laminectomy is a rational treatment strategy providing pain relief and good functional outcomes for wide range of patients with degenerative spinal stenosis and no instability, as well as minimizing risks of spinal fusion. Therefore, based on the current evidence and study findings, the trend for decompression and fusion chosen by some surgeons must be reviewed and the indications of fusion should be restricted to patients of lumbar stenosis accompanied by spinal instability or deformity.

## References


1. Hamdan TA, Massadi A, Chasib RJ. Principles of lumbar spinal instability. Basrsh: Al Ali Press; 2013.
2. Deyo RA. Treatment of lumbar spinal stenosis: a balancing act. Spine J. 2010;10(7):625-7.
3. Gardocki RJ, Park AL. Degenerative disorders of the thoracic and lumbar spine. In: Azar FM, Beaty JH, Canale ST, editors. Campell's operative orthopaedics. 13th ed. Philadelphia: Elsevier Inc.; 2017. p. 1645–718.
4. Lurie J, Tomkins-Lane C. Management of lumbar spinal stenosis. BMJ. 2016;352:h6234.
5. Deyo RA, Mirza SK, Martin BI, Kreuter W, Goodman DC, Jarvik JG. Trends, major medical complications, and charges associated with surgery for lumbar spinal stenosis in older adults. JAMA. 2010;303(13):1259-65.
6. Posner I, White AA, Edwards WT, Hayes WC. A biomechanical analysis of the clinical stability of the lumbar and lumbosacral spine. Spine (Phila Pa 1976). 1982;7(4):374-89.
7. WHO. Musculoskeletal conditions. WHO. World Health Organization; 2018.
8. Williams MG, Wafai AM, Podmore MD. Functional outcomes of laminectomy and laminotomy for the surgical management lumbar spine stenosis. J Spine Surg. 2017;3(4):580-6.
9. Jolles BM, Porchet F, Theumann N. Surgical treatment of lumbar spinal stenosis. Five-year follow-up. J Bone Joint Surg Br. 2001;83(7):949-53.
10. Fox MW, Onofrio BM, Hanssen AD. Clinical outcomes and radiological instability following decompressive lumbar laminectomy for degenerative spinal stenosis: A comparison of patients undergoing concomitant arthrodesis versus decompression alone. J Neurosurg. 1996;85(5):793-802.
11. Guha D, Heary RF, Shamji MF. Iatrogenic spondylolisthesis following laminectomy for degenerative lumbar stenosis: Systematic review and current concepts. Neurosurg Focus. 2015;39(4):E9.
12. Aalto T, Sinikallio S, Kröger H, Viinamäki H, Herno A, Leinonen V, et al. Preoperative predictors for good postoperative satisfaction and functional outcome in lumbar spinal stenosis surgery-a prospective observational study with a two-year follow-up. Scand J Surg. 2012;101(4):255-60.
13. Gelalis ID, Arnaoutoglou C, Christoforou G, Lykissas MG, Batsilas I, Xenakis T. Prospective analysis of surgical outcomes in patients

undergoing decompressive laminectomy and posterior instrumentation for degenerative lumbar spinal stenosis. Acta Orthop Traumatol Turc. 2010;44(3):235-40.

14. Williams KD. Spondylolisthesis. In: Azar FM, Beaty JH, Canale ST, editors. Campell's operative orthopaedics. 13th ed. Philadelphia: Elsevier Inc.; 2017. p. 1728–53.

15. Mulholland RC. The myth of lumbar instability: The importance of abnormal loading as a cause of low back pain. Eur Spine J. 2008;17(5):619-25.

16. Resnick DK, Watters WC, Mummaneni PV, Dailey AT, Choudhri TF, Eck JC, et al. Guideline update for the performance of fusion procedures for degenerative disease of the lumbar spine. Part 10: Lumbar fusion for stenosis without spondylolisthesis. J Neurosurg Spine. 2014;21(1):62-6.

17. Resnick DK, Watters WC, Sharan A, Mummaneni PV, Dailey AT, Wang JC, et al. Guideline update for the performance of fusion procedures for degenerative disease of the lumbar spine. Part 9: Lumbar fusion for stenosis with spondylolisthesis. J Neurosurg Spine. 2014;21(1):54-61.

18. Kreiner DS, Shaffer WO, Baisden JL, Gilbert TJ, Summers JT, Toton JF, et al. An evidence-based clinical guideline for the diagnosis and treatment of degenerative lumbar spinal stenosis (update). Spine J. 2013;13(7):734-43.

19. Munting E, Röder C, Sobottke R, Dietrich D, Aghayev E; Spine Tango Contributors. Patient outcomes after laminotomy, hemilaminectomy, laminectomy and laminectomy with instrumented fusion for spinal canal stenosis: a propensity score-based study from the Spine Tango registry. Eur Spine J. 2015;24(2):358-68.

20. Bydon M, De la Garza-Ramos R, Abt NB, Gokaslan ZL, Wolinsky JP, Sciubba DM, et al. Impact of smoking on complication and pseudarthrosis rates after single- and 2-level posterolateral fusion of the lumbar spine. Spine (Phila Pa 1976). 2014;39(21):1765-70.

21. Deyo RA. Fusion surgery for lumbar degenerative disc disease: Still more questions than answers. Spine J. 2015;15(2):272-4.