World Journal of Surgery and Surgical Research

Case Series
Published: 03 Oct, 2022

Nylon Cable-Tie Assisted Forearm Fasciotomy Wound Closure

*Hui CH[1], Ho CY[1] and Chang CW[1,2]**

[1]Department of Surgery, Far Eastern Memorial Hospital, Taiwan

[2]Graduate Institute of Biomedical Electronics & Bioinformatics, National Taiwan University, Taiwan

Abstract

Background: Closure of forearm fasciotomy wounds is challenging. Traditional methods for reconstruction are skin grafts or flaps. A skin graft or flap leaves an unpleasant appearance and requires a donor site. Initially, there is no skin defect or only limited defect. Presented here is a method utilizing looped cable ties for delayed primary closure of forearm fasciotomy wounds.

Methods: Patients who underwent fasciotomy of forearms for compartment syndrome and cable tie assisted closure from 2017 to 2020 in Far Eastern Memorial Hospital were included. Follow-up observations of all patients were conducted until December 2020. We retrospectively reviewed the cause of forearm compartment syndrome, the initial maximum width of the fasciotomy wounds, and the time for primary closure of the wounds.

Results: There were seven patients eligible for inclusion. Four patients suffered from compartment syndrome of the forearm caused by iatrogenic vascular rupture after the procedures. The other reasons for the compartment syndrome included open-type fracture and fasciitis. Emergency fasciotomy was arranged for all the patients, and cable ties were applied for delayed primary wound closure. Six of them, with the median initial maximum width of a wound of 5.15 cm [3.8 cm to 6.3 cm], achieved successful wound closure by cable ties without skin grafts or flaps on median day 12 [day 6 to 19]. One patient who had distal and proximal radius fracture received skin graft reconstruction after the application of cable ties for 14 days.

Conclusion: Cable ties--inexpensive and readily available materials--can be adjusted according to the different tension along the wound edges. They provide a simple, effective, and safe way to close difficult forearm fasciotomy wounds.

Keywords: Forearm compartment syndrome; Fasciotomy; Nylon cable tie; Delay primary wound closure

OPEN ACCESS

***Correspondence:**
Che-Wei Chang, Graduate Institute of Biomedical Electronics & Bioinformatics, National Taiwan University, Far Eastern Memorial Hospital, New Taipei, Taiwan, Tel: +886-936-660-678;
E-mail: b92401068@gmail.com

Received Date: *13 Sep 2022*
Accepted Date*: 27 Sep 2022*
Published Date*: 03 Oct 2022*

Citation:
Hui CH, Ho CY, Chang CW. Nylon Cable-Tie Assisted Forearm Fasciotomy Wound Closure. World J Surg Surgical Res. 2022; 5: 1410.

Background

Forearm fasciotomy is a procedure to release compartment pressure. Compartment syndrome of the forearm is an uncommon diagnosis. The etiology can be trauma or non-trauma. The most reported cause of trauma in adults is the fracture of the distal radius, whereas, in children, the most common cause is the supracondylar fracture of the humerus [1]. Distal radius fractures count for 18% of all cases of forearm compartment syndrome [2]. Other causes include burns, penetration wounds, artery injury, extravasation of drugs or intravenous fluids, reperfusion injury, and infection. Without timely management within 6 h from the onset, the reported rate of complication increases to as high as 42%, with complications arising such as digit contracture, gangrene, and neurologic deficit [3].

Usually, there is no skin defect or only a limited defect initially. After fasciotomy, the wound edge of the skin flap retracts gradually. Then, as the swelling of forearm tissues subsides, the wound edge becomes too retracted to be closed. More than 60% of patients require a skin graft to resurface the forearm [2]. Skin graft leaves an unpleasant appearance and requires a donor site, unlike delayed primary closure [4]. Even though the donor site for the free forearm flap can be closed if the defect is less than 20% of the length of the ulnar propeller flap [5], it is worth a try to close the fasciotomy wound by using mechanical creep of the skin [6].

Many techniques and materials have been recommended for delayed primary closure wounds, such as rubber bands, surgical strips, and C wires [7,8]. Cable ties made of nylon are the most

Table 1: Summary of patient characteristics.

No.	Age	Gender	Etiology	Details	Maximum width (cm)	Time to complete closure	Time from fasciotomy to begin closure (Days)
1	67	Female	Compartment syndrome (iatrogenic)	Radial artery rupture	5.1	19	4
2	71	Male	Compartment syndrome (iatrogenic)	Radial artery rupture	5.2	14	6
3	72	Male	Compartment syndrome (iatrogenic)	Radial artery rupture	5.5	14	7
4	34	Male	Compartment syndrome (iatrogenic)	Cubital vein rupture	6.3	10	Immediate
5	48	Male	Compartment syndrome (Trauma)	Distal radioulnar fracture, open	4.1	6	Immediate
6	56	Female	Infection	Fasciitis of forearm	3.8	17	7
7	51	Male	Compartment syndrome (Trauma)	1.Distal radius fracture, closed	9.7	N/A	7

popular, easily available, and low-cost suture materials. Cable ties provide 8 kg to 25 kg of traction force, depending on their diameter, to maintain suitable tension. Cable ties are also available in a wide variety of lengths which can be utilized to close wounds of any size. Ties can also be used in isolation or connected in a series to expand suture length. In this study, we report on seven cases with forearm fasciectomy wounds due to different etiologies and the surgical outcomes of wound closure using nylon cable ties.

Methods

Patient selection

This was a retrospective review study of patients who underwent fasciotomy of forearms and wound closure with nylon cable ties from January 2017 to December 2020 at Far Eastern Memorial Hospital. The research ethics review committee of our institution has approved this study protocol (111036-E). Patients who were under the age of eighteen or did not have adequate follow-up until wounds healed were excluded. Emergency fasciotomy/fasciectomy and consequent wound closure with cable ties were performed after we obtained surgery consent from patients or families. Some patients were unable to sign the consent because of their critical condition, which had been signed by their families. All pictures of wounds were taken for medical records and research under the consent of patients or families. We reviewed the cause of forearm compartment syndrome, the initial maximum width of the fasciotomy wound, and the time for primary closure of the wound.

Surgical technique

After fasciotomy/fasciectomy, meticulous hemostasis was performed to cease bleeding following massive irrigation. Sterile wet gauzes were applied to cover and protect the exposed muscles and tendons. Nylon cable ties of proper size were selected and placed across the wound perpendicular to the wound edges from the outer two ends toward the center of the fasciotomy wound at approximately 4 cm to 6 cm intervals. Each cable tie was first anchored by 2 or 3 skin staples placed 1.5 cm from one of the wound edges. Then on the opposite side of the wound edge, cable ties were similarly placed, anchored, and stapled. Cable ties were looped up orderly to decrease wound sizes. Distal perfusion was observed for 20 min before patients were released from the operating room. An oximeter was placed on the digits of the injury site, and pulsation of the radial artery was checked Q1H with a handheld Doppler. Sterile gauze was changed every day and replaced with hydro-fiber dressing (Aquacel) until no blood or hematoma was found. Cable ties were tightened up 0.5 cm to 0.3 cm depending on the tension of the wound every 2 or 3 days. The tie was loosened when the skin flap showed blanching or when distal circulation was compromised. The wound bed was debrided to remove slough tissue, and the fixation site of the staples was adjusted slightly to avoid pressure ulcers every week. Final closure was performed when there was no longer enough tension to interfere with the placement of regular sutures.

Results

Seven patients underwent forearm fasciotomy and application of cable ties to close the wound. Six patients had successfully closed wounds without skin grafts. Table 1 shows the summary of patient characteristics. Because the two most frequent signs of compartment syndrome are swelling followed by excessive pain 3, diagnosis in our

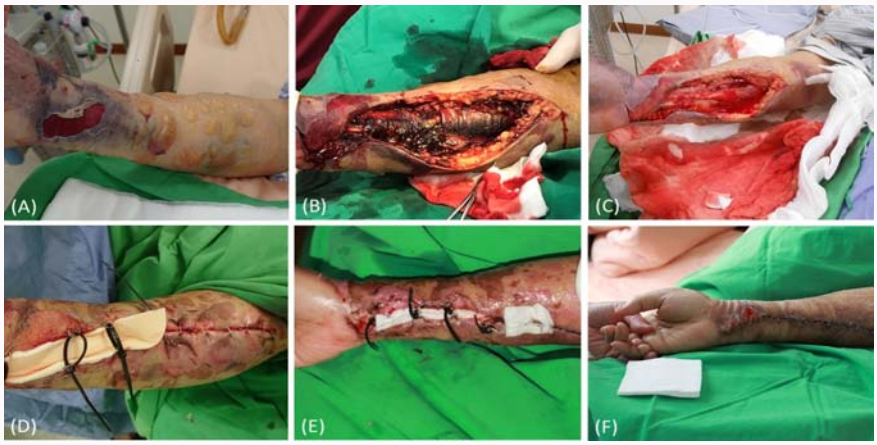

Figure 1: (A) Compartment syndrome with bulla formation. (B) Intramuscular hematoma. (C) Most flexor muscles are still viable. (D) Day 6 after applying cable ties. (E) Day 11 after cable ties application. (F) Day 2 after the closure of the fasciotomy wound.

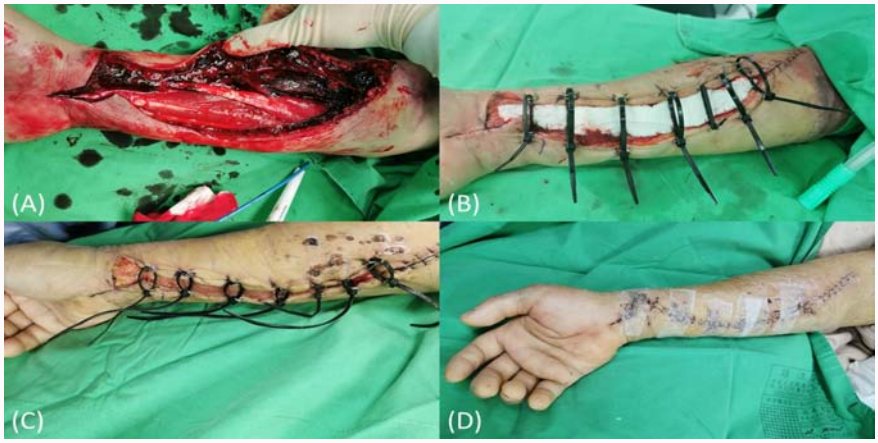

Figure 2: (A) Radial artery rupture with intramuscular hematoma. (B) Day 6 after application of cable ties. (C) Day 11 after applying cable ties. (D) Day 2 after the closure of the fasciotomy wound.

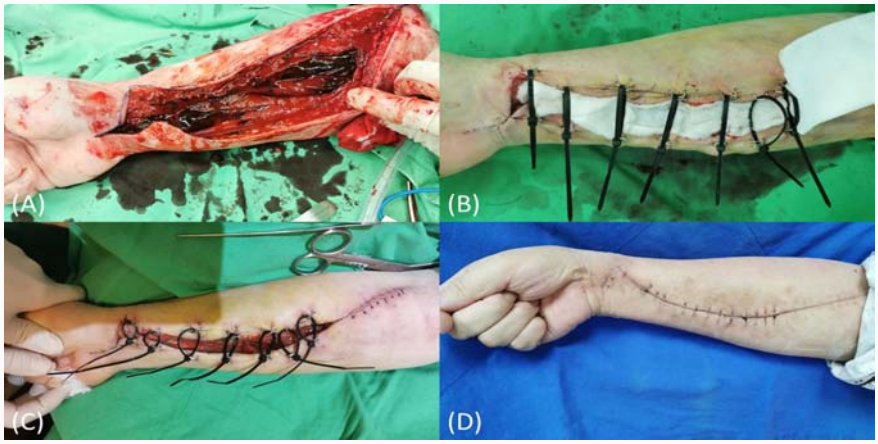

Figure 3: (A) Radial artery rupture with intramuscular hematoma. (B) Day 7 after applying cable ties. (C) Day 11 after applying cable ties. (D) Day 40 after the closure of the fasciotomy wound.

patient group was not easy. Four patients were undergoing surgery, and the other three were under sedation in ICU, which made them unable to express pain. They were diagnosed by our colleagues under keen observation, which was promptly confirmed by measuring the compartment pressure. The details of the treatment course are addressed below.

Case 1

This 67-year-old woman who was diagnosed with Non-ST Elevation Myocardial Infarction (NSTEMI) had undergone Percutaneous Transluminal Angioplasty (PTA) via the right radial artery (Figure 1). Compartment syndrome of the right forearm was noted the same day of the procedure. Emergent fasciotomy was performed to decompress and remove the hematoma. Cable ties were applied four days after the fasciotomy when the muscles showed more viability. After 19 days, the fasciotomy wound was completely closed. The patient showed normal scarring and symmetric muscle power with the contralateral side (Video 1).

Case 2

This 71-year-old man presented with out-of-hospital cardiac arrest due to STEMI and had undergone PTA *via* the right radial artery after cardiac pulmonary resuscitation and return of spontaneous circulation. Compartment syndrome of the right forearm was noted after the procedure. Emergency fasciotomy and carpal tunnel release were performed on the same day of PTA (Figure 2). Cable ties were applied six days after fasciotomy. The fasciotomy wound was completely closed 14 days after application. Unfortunately, the patient expired seven days after wound closure because of deteriorating heart function.

Case 3

This 72-year-old man received PTA from the right radial artery due to NSTEMI. He experienced the complication of right forearm compartment syndrome on the same day of the operation. Emergency fasciotomy was performed to remove the hematoma and repair the radial artery (Figure 3). Cable ties were administered seven days after fasciotomy. Fourteen days after application, the fasciotomy wound was successfully closed. The wound showed acceptable cosmetic results approximately 1.5 months after wound closure.

Case 4

This 34-year-old man was diagnosed with cholangiocarcinoma. There was massive bleeding during liver lobectomy. Due to unstable hemodynamics, a large peripheral intravenous line was built at the right cubital vein for massive transfusion with the assistance of a pressure infusion bag. The high pressure or transfusion caused the rupture of the right cubital vein. The neglected situation and

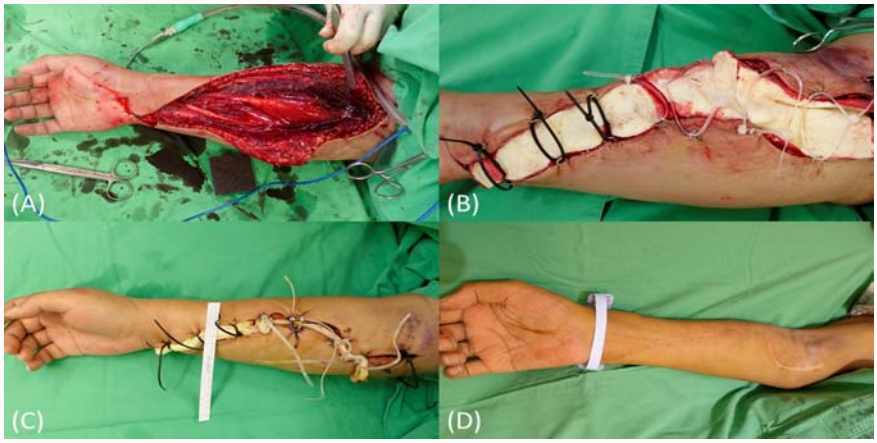

Figure 4: (A) Cubital and cephalic vein rupture with intramuscular hematoma. (B) Immediately after the application of cable ties. (C) Day 10 after applying cable ties. (D) Day 12 after the closure of the fasciotomy wound.

Figure 5: (A) Forearm fasciitis with subcutaneous abscess. (B) After excision of necrotic skin and flexor tendons. (C) Intra-op photo showing the application of cable tie. (D) Day 7 after applying cable ties. (E) Day 15 after cable ties application. (F) Day 3 after wound closure.

continuous infusion resulted in compartment syndrome (Figure 4). Fasciotomy and hematoma evacuation was performed along with liver surgery. Cable ties were immediately applied for skin approximation. The wound was closed successfully ten days after application.

Case 5

This 48-year-old man suffered from a right open distal radioulnar fracture, ulnar artery rupture, multiple flexor tendon injuries, and ulnar and median nerve injury resulting from a traffic accident. He underwent emergency percutaneous internal fixation following artery, tendons, and nerve repair. Because of tissue swelling, the wound could not be closed, and cable ties were applied. After six days of cable tie traction, the wound was completely approximated.

Case 6

This 56-year-old female had a medical history of left breast cancer post breast conservative treatment and axillary lymph node dissection. She also had experienced a left distal radius fracture without proper fixation resulting in left wrist deformity since childhood. During chemotherapy treatment, her left forearm and palm developed multiple abscesses and hemorrhagic bulla with septic shock. Emergency fasciotomy and fasciectomy were performed twice to remove nonviable tissue (Figure 5). Some necrotic extensor tendons were excised as well. Cable ties were applied three days after the second fasciectomy. Since some skin edges were trimmed, it took 17 days to close the wound with cable ties.

Case 7

This 51-year-old male had a history of hypertension and alcoholism. He got drunk and fell down a flight of stairs. The accident resulted in right distal radius closed fracture, right elbow open dislocation and proximal radius fracture, brachial artery tear, right shoulder anterior dislocation, multiple rib fractures, scalp laceration, and multiple contusions of the extremities (Figure 6). Shoulder reduction was performed at the emergency department. Compartment syndrome was noticed. Emergency elbow reduction, fixation of radius fracture with C wires, fasciotomy, and then brachial artery repair were performed. The compartment syndrome was resolved but muscle swelling only slightly subsided during daily wound care. The cable ties were applied on Day 7. There were two factures of the forearm, thus tissue swelling was not completely resolving. After application of cable ties for 14 days, the maximum width of the wound edge decreased from 9.7 cm to 6.1 cm. We reconstructed the wound with a Split Thickness Skin Graft (STSG).

Discussion

The cable tie was initially invented in the 1950s by an electrical company, Thomas & Beths, for fastening cables and wires under the

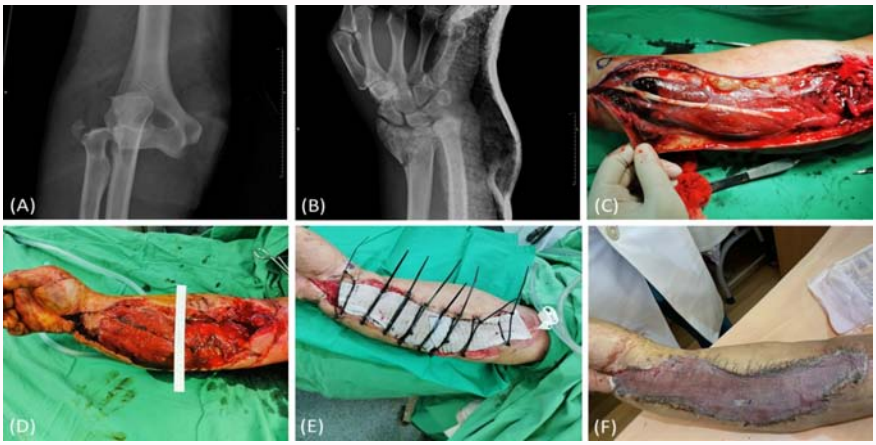

Figure 6: (A) Open dislocation of the elbow joint with proximal radius fracture. (B) Distal radius fracture with contusion of carpal bones. (C) Compartment syndrome of the forearm. (D) No overt subsiding of tissue swelling. (E) Cable ties decreased the width of the wound edge. (F) Ten days after STSG.

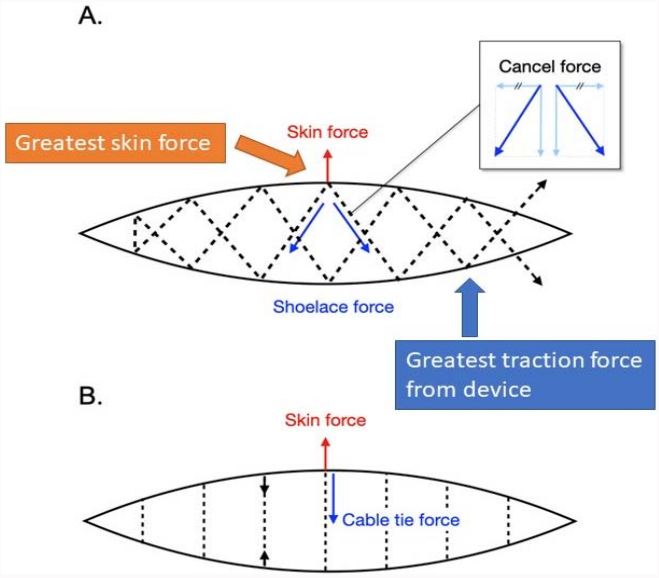

Figure 7: (A) For the shoelace device, the forces of the x vector do not contribute to the tension for wound closure. (B) The force is parallel to the skin face without diversion.

brand name Ty-rays. It has nylon tape on one end with a ratchet and a small opening on the other end, allowing the nylon tape to pass through, creating a loop to hold things together. In addition to its industrial application, the application of cable ties reached the medical field at the beginning of the 21st century. It was first reported in a preliminary study in the porcine model for encircling a kidney pole before partial nephrectomy in 2001 [9,10]. In 2007, cable ties were also employed by a proctologist as a cutting Seton for drainage [11]. Before the use of nylon cable ties began, many materials were proposed as a Seton, such as a rubber band, piece of a glove, Penrose drain, steel wire, silastic tube, and braided suture [12]. None of these materials can provide the convenience of exertion tension as a cable tie. For a complex anal fistula close to the sphincter muscle, a cable tie Seton creates fibrosis and cuts off the fistula at the same time in a bid to preserve the function of the sphincter muscle and avoid incontinence [13]. For patients undergoing head and cancer surgery or who have a face burn injury, the defect of the face may prevent the fixation of an endotracheal tube. Gray et al. reported the use of cable ties for the fixation of an endotracheal tube at the palate while performing operations in 2010 [14]. Surgical assistants may not be available for every operation. Evren et al. reported the use of cable ties as a surrogate for the traction provided by a surgical assistant as it sustained appropriate tension during smooth de-epithelialization [15]. Recently, cable ties made of poly-ether-ether-ketone have become a new method for sternotomy closure. A prospective study showed cable ties were not inferior to traditional stainless wires in infection control, and provided better stability [16]. Cable ties are easier to apply than stainless wires, resulting in slightly decreased operation time [17].

The application of cable ties is employed for dynamic wound closure, a concept that was proposed in the 1970s [18,19]. There are several commercially available devices, such as SureClosure®, ARBA®, DermaClose®, DynaClose®, DermaClip®, and TopClosure®. Depending on the ratio of traction force to skin tension, these are divided into two categories: Shoelaces and individual traction devices. Most wound closing devices are individual traction devices, whereas DermaClose® employs the shoelace technique [20]. There are some disadvantages of shoelace traction devices. First, the force vector is

oblique to the skin traction force, which means the x component of the force vector, which is parallel to the axis of the wound, doesn't contribute to the tension provided for wound closure. Besides, the x component of the left and right force at one skin anchor is opposite and will be canceled out during traction (Figure 7), unlike the force fully vertical to the long axis of the wound provided by the other dynamic wound closure devices and cable ties used as individual traction devices. Second, every point of the wound edges requires a different force to approximate. The continuous thread of shoelaces does not allow for fine adjustment of tension at every point. As with a shoe, the maximum traction force of the device is on the end of the wound where the thread is tied, but the wound edge requires the most force in the middle of the wound.

SureClosure® is an early-developed intervention used for dynamic wound closure [21,22]. The application is an invasive procedure using a U pin on the epidermis and intradermal pins to anchor the skin flap. An external stretching device (bar) is used for traction. The device is not small, and the linear bar cannot be fitted to areas of large curvatures, such as the forearm, dorsal foot, or scalp. The application of ARBA® is also an invasive procedure where the device is placed under the skin edge and then anchored to the skin with stainless-steel pins. Instead of using a bar, ARBA® passes pliable rubber-band-like elastomers through the anchor pin to adapt to the curvature of the abdomen [23,24]. New devices such as DynaClose® and DermaClip® are less invasive, using adhesive dressing to tape on the skin edges [25,26]. The counter force to skin traction from adhesion dressing is limited. They are designed to close a wound with a gap of less than 2 cm, not a fasciotomy wound of the extremities. TopClosure® has a similar mechanism as nylon cable ties [26]. Both devices requires in staples or sutures for fixation on the skin and installation of the polymer strap. Cable ties have many advantages over such commercial products. Nylon cable ties are inexpensive and easily sterilized (less than 0.01 USD for a single strap). There are available in a wide variety of lengths and diameters, making them suitable for different tension requirements along any wound edge of the human body, which is not the case for commercial products. Moreover, the cable ties can be used to immobilize other medical devices or as a medical device, such as a self-retractor and tourniquet [27]. Nylon cable ties are perfect for use in emergencies or areas without proper medical supplies, such as in wars.

However, there are potential draw backs to this technique. The application of traction may cause the redevelopment of compartment syndrome and needs constant monitoring. The cable ties and staples may cause pressure ulcers in underlying tissues. Before total closure, waiting for the swelling of the wound to subside bears the risk of infection and tissue necrosis.

Conclusion

Forearm compartment syndrome is an uncommon diagnosis. The traditional method of reconstruction is to perform a skin graft. With proper sterilization, cable ties have become a convenient dynamic wound closure system widely employed in various specialized medical procedures ranging from closure of midline sternal wounds to use as a tourniquet. In this study, we proposed gradual tightening with nylon cable ties to close forearm fasciotomy wounds. They provide a readily available, effective, and economical solution for closing these difficult wounds.

Ethical Approval

This is a retrospective case series study, which has been approved by the research ethics review committee of Far Eastern Memorial Hospital (111036-E) on March 15, 2022. The document is uploaded to the supplementary file. The study was performed in accordance with the Declaration of Helsinki. All patients or their authorizers gave written informed consent before the operations.

References

1. Kistler JM, Ilyas AM, Thoder JJ. Forearm compartment syndrome: Evaluation and management. Hand Clin. 2018;34(1):53-60.
2. Kalyani BS, Fisher BE, Roberts CS, Giannoudis PV. Compartment syndrome of the forearm: A systematic review. J Hand Surg Am. 2011;36(3):535-43.
3. Duckworth AD, Mitchell SE, Molyneux SG, White TO, Court-Brown CM, McQueen MM. Acute compartment syndrome of the forearm. J Bone Joint Surg Am. 2012;94(10):e63.
4. Rogers GF, Maclellan RA, Liu AS, Taghinia AH, Labow BI, Meara JG, et al. Extremity fasciotomy wound closure: comparison of skin grafting to staged linear closure. J Plast Reconstr Aesthet Surg. 2013;66(3):e90-1.
5. Ching-Hua H, Yur-Ren K, Sheng-Fa Y, Chi-Cheng L, Seng-Feng J. Primary closure of radial forearm flap donor defects with a bilobed flap based on the fasciocutaneous perforator of the ulnar artery. Plast Reconstr Surg. 2004;113(5):1355-60.
6. Wilhelmi BJ, Blackwell SJ, Mancoll JS, Phillips LG. Creep *vs*. stretch: A review of the viscoelastic properties of skin. Ann Plast Surg. 1998;41(2):215-9.
7. Kenny EM, Egro FM, Russavage JM, Spiess AM, Acartürk TO. Primary closure of wide fasciotomy and surgical wounds using rubber band–assisted external tissue expansion: A simple, safe, and cost-effective technique. Ann Plast Surg. 2018;81(3):344-52.
8. Li-Fu C, Jiunn-Tat L, Hsu H, Meng-Si W. Simple skin-stretching device in assisted tension-free wound closure. Ann Plast Surg. 2017;78(3 Suppl 2):S52-7.
9. Cadeddu JA, Corwin TS. Cable ties compression to facilitate laparoscopic partial nephrectomy. J Urol. 2001;165(1):177-8.
10. Gofrit ON, Harlev M, Rosenberg S, Pode D, Zorn KC, Shalhav AL, et al. Pure "cable-tie partial nephrectomy": A porcine model. Surg Endosc. 2010;24(12):3229-32.
11. Gurer A, Ozlem N, Gokakin AK, Ozdogan M, Kulacoglu H, Aydin R. A novel material in seton treatment of fistula-in-ano. Am J Surg. 2007;193(6):794-6.
12. Subhas G, Bhullar JS, Al-Omari A, Unawane A, Mittal VK, Pearlman R. Setons in the treatment of anal fistula: Review of variations in materials and techniques. Dig Surg. 2012;29(4):292-300.
13. Memon AA, Murtaza G, Azami R, Zafar H, Chawla T, Laghari AA. Treatment of complex fistula in ano with cable-tie seton: A prospective case series. ISRN Surg. 2011;2011:636952.
14. Gray R, Rode H. Intra-operative endotracheal tube stabilisation for facial burns. Burns. 2010;36(4):572-5.
15. Evren I, Canter HI, Yucel E. Deepithelialization of breast in reduction mammoplasty using cable tie as breast tourniquet. Indian J Plast Surg. 2013;46(01):152.
16. Marasco SF, Fuller L, Zimmet A, McGiffin D, Seitz M, Ch'ng S, et al. Prospective, randomized, controlled trial of polymer cable ties versus standard wire closure of midline sternotomy. J Thorac Cardiovasc Surg. 2018;156(4):1589-95. e1581.
17. Melly L, Gahl B, Meinke R, Rueter F, Matt P, Reuthebuch O, et al. A new

cable-tie-based sternal closure device: Infectious considerations. Interact Cardiovasc Thorac Surg. 2013;17(2):219-23.

18. Barrer S, Pavlides C, Matsumoto T. Ideal laparotomy closure: Comparison of retention sutures with new retention bridging devices. Am Surg. 1976;42(8):582-4.

19. Wang X, Zhang Y, Kiu-Huen NS, Zhang Z, Pu Z, Yang H, et al. Using modified skin-stretching technique as an alternative solution for the closure of moderate and extensive skin defects. Rejuvenation Res. 2021;24(6):407-16.

20. Santiago GF, Bograd B, Basile PL, Howard RT, Fleming M, Valerio IL. Soft tissue injury management with a continuous external tissue expander. Ann Plast Surg. 2012;69(4):418-21.

21. Subramania K, Mohit S, Sasidharan P, Abraham M, Arun P, Kekatpure V. Sure closure-skin stretching system, our clinical experience. Indian J Plast Surg. 2005;38(02):132-7.

22. Futran ND. Closure of the fibula free flap donor site with the sure-closure skin-stretching device. The Laryngoscope. 1996;106(12 Pt 1):1487-90.

23. Urbaniak RM, Khuthaila DK, Khalil AJ, Hammond DC. Closure of massive abdominal wall defects: A case report using the Abdominal Reapproximation Anchor (ABRA) system. Ann Plast Surg. 2006;57(5):573-7.

24. Haddock C, Konkin DE, Blair NP. Management of the open abdomen with the Abdominal Reapproximation Anchor dynamic fascial closure system. Am J Surg. 2013;205(5):528-33.

25. Doumit J, Vale R, Kanigsberg N. Dynaclose tape: A practical alternative to punch biopsy site closure. J Cutan Med Surg. 2013;17(1):62-5.

26. Ko J, Freed JS. A recent advance in the closure of skin wounds on fragile skin. Case Rep Emerg Med. 2021;2021:6687961.

27. Cadeddu JA, Corwin TS, Traxer O, Collick C, Saboorian HH, Pearle MS. Hemostatic laparoscopic partial nephrectomy: Cable-tie compression. Urology. 2001;57(3):562-6.