World Journal of Surgery and Surgical Research

Research Article
Published: 23 Jan, 2019

Evaluation of the Effect of Temporarily Controlling of External Carotid Artery and Immediate Obturator Design on patients Undergoing Partial Maxillectomy

Hossam Abdelkader El-Fol[1], Ashraf E. Eskander[2], Mohamed Galal Beheiri[3] and Waleed Ali ALzaqri[3]*

[1]Department of Surgical Oncology, Menofia University, Egypt

[2]Department of Oral and Maxillofacial Prosthesis, Cairo University, Egypt

[3]Department of Oral and Maxillofacial Surgery, Cairo University, Egypt

Abstract

Purpose: Management of malignant maxillary tumors with reduces of bleeding, totally eradication of tumor, and maintaining facial contour and rapid re-establishment of mastication.

Patients and Method: In group I, surgical treatment was started with neck dissection and vascular control of external carotid artery, partial maxillectomy followed by immediate obturator with a buccal-retaining flange and artificial teeth. While in group II, surgical treatment started by partial maxillectomy, classic neck dissection followed by conventional immediate obturator without artificial teeth. Electromyographic (EMG) activities of the masseter and temporalis muscles of the intact and surgical sides were recorded for all patients, one day before surgery; and three months after surgery using Caldwell Excel EMG/EP appliance with surface electrodes.

Result: Of 20 patients showed EMG activities highly significant increase in suggested design in both muscles of intact and defect sides in compare to other design. No significant difference of blood loss between both groups.

Conclusion: Vascular control of external carotid artery showed clean surgical field during maxillectomy that facilitate check margin of surgical ablation from any residual lesion, also reduce time waste of obturator adjustment. Design of obturator in group I showed more muscle activity and improve of psychological aspect of the patients.

Keywords: Maxillectomy; Immediate obturator; External carotid artery

OPEN ACCESS

Correspondence:
Waleed Ali ALzaqri, Department of Oral and Maxillofacial Surgery, Cairo University, 23 Suleiman Alfransaoi St. Old Cairo, Cairo City, Egypt, Tel: 00201014436119;
E-mail: waleed.alzaqri@yahoo.com

Received Date: *06 Dec 2018*
Accepted Date*: 21 Jan 2019*
Published Date*: 23 Jan 2019*

Citation:
El-Fol HA, Eskander AE, Beheiri MG, ALzaqri WA. Evaluation of the Effect of Temporarily Controlling of External Carotid Artery and Immediate Obturator Design on patients Undergoing Partial Maxillectomy. World J Surg Surgical Res. 2019; 2: 1095.

Introduction

Malignant tumors of the upper gum and hard palate account for 1% to 5% of malignant neoplasms of the oral cavity; two thirds of the lesions which involve these areas are squamous cell carcinomas. Most of these carcinomas are diagnosed late, when they invade the underlying bone [1].

Persons who exhibit deformities and congenital or acquired facial defect become socially stigmatized because society place value on facial appearance. The primary objective in treating the tumors in maxilla is to eliminate the disease and improve the quality of life [2].

There are many surgical techniques for treatment of malignant tumors of hard palate and maxilla, inferior maxillectomy, midline maxillectomy, hemimaxillectomy, partial maxillectomy, or total maxillectomy. Selection of one of them depend on previously evaluated the location, extent of the lesion, histotype, patient's age and general state of health [1].

Patients at highest risk for regional lymph node metastasis have been difficult to identify based on clinical parameters alone. Management of the clinically negative neck in patients with maxillary tumor has received little attention compared with other oral cavity subsites. Therefore, a selective neck dissection is commonly recommended for patients with maxillary tumors [3].

The use of immediate surgical obturator prosthesis has become the standard of care for patients undergoing maxillectomies, providing support and protection for the surgical dressing and improvement of speech and deglutition, with minimal post-surgical infection and scar contracture

Figure 1: The stone cast after modification of the area of future resection for patients of group I.

Figure 2: The finished immediate surgical obturator for patients of group I.

Figure 3: The stone cast after modification of the area of future resection or patients of group II.

Figure 4: The finished immediate surgical obturator for patients of group II.

Figure 5: Temporary vascular occlusion of the external carotid artery above the level of the superior thyroid artery was done by vascular clamp before tumor resection in group I (Patient No 7).

Figure 6: Surgical field after complete resection of primary tumor with safety margin, left hemimaxillectomy in group I (Patient No 7).

formation [2,4,5]. Also, the immediate obturator reduces oral contamination of the wound, eliminates the need for nasogastric tube (as it permits deglutition) and reduces the period of hospitalization, thus improving the quality of life in these patients, post-operatively [6,7].

Immediate surgical obturation is particularly suitable for dentulous patients requiring a partial or sub-total maxillectomy because the remaining teeth can be useful in the retention of the prosthesis. Immediate surgical obturation progressed more quickly and had a more rapid return to normal function [8].

Many authors recommended the immediate prosthesis to be simple, light in weight, inexpensive, with round 18-guage wrought gold or stainless steel wire retainers as well as with holes at the interproximal extensions so that the prosthesis can be wired to the teeth at the time of surgery [4,6]. Many materials have been used to make immediate and intermediate obturator prostheses for the hemimaxillectomy patient. The weight of the obturator prosthesis is a major hindrance and Reconstruction of such defects should achieve facial symmetry with good esthetic results [9].

The major problems encountered during surgery are the difficulty of bleeding control from ascending palatine artery, another maxillary artery branches and the pterygoid plexuses in the posterosuperior region of hard palate, also after maxillectomy is a communication between the oral cavity and the nose or paranasal sinuses resulting in major dysfunction in speech and swallowing which have a very negative psychological effect. These problems can be overcome with good homeostasis and an immediate prosthesis but to be fully successful, coordinated work is required between the surgeon and the maxillofacial prosthodontist before, during and after surgery [10,11].

The management of malignant maxillary and hard palate tumors with reduces of bleeding and totally eradication of tumor with safety margin and immediate restore the function and aesthetic was our aim in this study.

Patient and Methods

This study was performed in Surgical Oncology Department, Faculty of Medicine, Menofia University, Oral and Maxillofacial Surgery Department and Oral and Maxillofacial Prosthetic Department, Faculty of Oral and Dental Medicine, Cairo University

between March 2006 and July 2015 after approval by the hospital's Ethics Committees. It involved 20 maxillectomy obtained from 20 patients with lesions in upper jaw. All the patients provided informed consent. Following thorough clinical examination and routine preoperative laboratory tests, a search of locoregional and distant metastases were done with Computed Tomography (CT) scan, and Magnetic Resonance Imaging (MRI). Maxillary and hard palate tumors were included and randomized into two equal groups, each of ten patients. Where patients with local recurrent, previous radiotherapy, chemotherapy or compromised were excluded.

For patients of group I receiving vascular controls to the external carotid artery during neck dissection by vascular clamp before resection of the tumors. The design of the immediate obturator included a buccal-retaining flange, anterior and posterior artificial teeth (with two millimeters occlusal clearance posteriorly) and a hollow obturator bulb extending into the defect after complete resection of tumor with safety margin.

For patients of group II, classic neck dissection was performed and a conventional immediate obturator was constructed in the form of acrylic plate to block the surgical defect and wrought wire clasps for retention after complete resection of the primary tumor with safety margin.

Obturator construction was performed by taken Upper and lower alginate impressions in properly modified stock trays and poured immediately into dental stone to obtain the working model. Interocclusal record was made and used for mounting casts on the articulator.

The line of surgical resection was marked on the working cast. For patients of group I, the cast was modified at the area of future resection by removal of the teeth from the model and lowering the height of the ridge area to the level of the palate. In addition, a small concavity was made midway between the resection line and the lateral cast border (Figure 1). The immediate surgical obturator was waxed up with a hollowed bulb and a buccal-retaining flange with two U-shaped wire loops added anterior and posterior to the remaining natural teeth for retention. Then, acrylic artificial teeth of suitable mold, shape and shade were set up to be properly oriented with the lower teeth, but with two millimeters occlusal clearance posteriorly. Waxing up was completed and the obturator was processed into heat-cured acrylic resin (Figure 2).

For patients of group II, the maxillary cast was modified by removal of the teeth from the model at the area of future resection and reducing the ridge height by about two to three millimeters (Figure 3). Multiple wrought wire clasps were adapted to at least three of the posterior teeth and then waxing up of the obturator was completed in the form of a simple plate and processed into heat-cured acrylic resin (Figure 4).

Three to four concavities were drilled in the lateral side of the obturator for patients of group I and two wire loops were fixed to the fitting surface of the obturator using self-curing resin for patients of group II for the retention of impression compound in both groups at the time of obturator insertion.

Surgical phase

Surgical procedures started with suprahyoid neck dissection and vascular controls to the external carotid artery before primary tumor resection in group I (Figure 5,6). While in group II, surgical procedure started with primary tumor resection.

Figure 7: The immediate surgical obturator in the patient's mouth after surgical resection in left side group I (Patient No 8).

Figure 8: The surgical obturator in the patient's mouth for group I with buccal cusps clearance. Ten days post-operative (Patient No 7).

After complete tumor resection (hemimaxillectomy) with safety margin in both groups, the obturator was tried in the patient's mouth and the necessary adjustments were carried out. For patients of group I, posterior occlusal clearance was also checked properly. Impression compound was softened in warm water, fixed to the obturator and molded to provide lip and cheek support. Tissue conditioning material was added anteriorly and posteriorly to ensure adequate seal and avoid any trauma from the compound (Figure 7). The flap was repositioned and checked for proper facial contours before suturing. Patients were instructed for soft diet for ten days, after which the obturator was removed and any necessary adjustments were carried out; then, tissue conditioning material was added to the obturator after removal of the surgical pack (Figure 8). All patients were asked to come back every ten days for making the necessary adjustments.

Electromyographic evaluation

The electromyographic activities of the masseter and temporalis muscles of the intact and surgical sides were recorded for all patients, one day before surgery; and three months after surgery using Caldwell Excel EMG/EP appliance with surface electrodes. Four surface electrodes were fixed at the maximum power point of each muscle in addition to two widely separated reference electrodes. A plastic template was constructed for each patient as a reference for the position of the surface electrodes in the follow-up period. The mean voltage, Root Mean Square (RMS) values and power of both muscles on both sides were recorded during clenching and chewing soft food on the intact side at each time of recording. The mean voltage represents the voltage difference between two points during activity. RMS values denote the square root of the means of the square values of the highest peaks of activities. The power indicates the amount of joules exerted during muscle action. The data collected was tabulated and statistically analyzed.

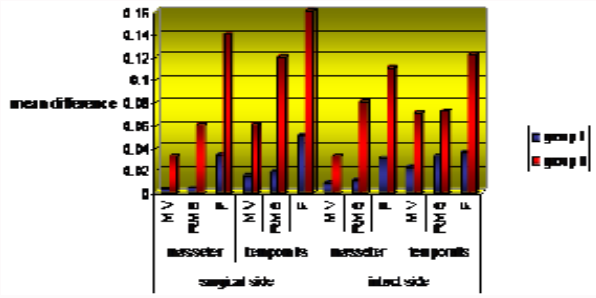

Figure 9: Histogram showing mean differences in the electromyographic activities during clenching for both groups.

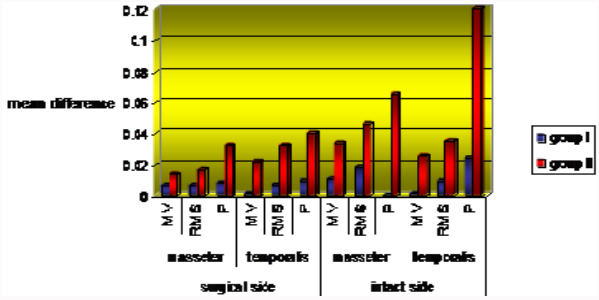

Figure 10: Histogram showing mean differences in the electromyographic activities during chewing soft food for both groups.

Table 1: Study group (group I).

Serial	Age	Sex	Pathology	Blood loss	Duration of Procedure (min)
1	58	male	MEC grade 2	100 cc	150
2	53	male	MEC grade 2	90 cc	160
3	46	female	ACC grade 2	160 cc	150
4	65	male	SCC grade 1	150 cc	150
5	46	male	SCC grade 2	150 cc	150
6	68	female	ACC grade 1	180 cc	150
7	59	male	SCC grade 2	66 cc	150
8	85	male	SCC grade 2	100 cc	170
9	57	female	Melanoma grade 1	100 cc	160
10	51	male	Melanoma grade 1	80 cc	180

SCC: Sequomas Cell Carcinoma; MEC: Mucoepidermoid Carcinoma; min: minute; ACC: Adenocytic Carcinoma

Table 2: Control group (group II).

Serial	Age	Sex	Pathology	Blood loss	(min)Duration of Procedure
1	59	female	SCC grade 1	150 cc	180
2	45	male	SCC grade 2	160 cc	180
3	59	Female	SCC grade 2	200 cc	190
4	60	male	ACC grade 2	250 cc	200
5	45	female	SCC grade 4	140 cc	210
6	57	female	SCC grade 1	150 cc	180
7	58	female	SCC grade 1	150 cc	180
8	70	Male	SCC grade 1	150 cc	180
9	80	female	ACC grade 2	150 cc	180
10	65	female	SCC grade 1	150 cc	180

SCC: Sequomas Cell Carcinoma; MEC: Mucoepidermoid Carcinoma; min: minute; ACC: Adenocytic Carcinoma

Results

The study groups included 20 patients (13 males and 7 females), with a mean age of 58.4 years (range 29 to 84) at treatment. The pathologic diagnoses were untreated squamous cell carcinoma in 12 patients, adenoid cystic carcinoma in 4, and recurrent squamous cell carcinoma in 2 patients and melanoma in 2 patients (Table 1,2).

The approaches for ablation were intraoral resection in 17 patients, lip split in 3 patients, and a total of 20 patients underwent suprahyoid neck dissection.

Duration of Operating time in both groups was the primary outcome which evaluated intra-operative. Where in group I ranged 150 min to 180 min (minute) with mean time 165 min; where 180 min to 210 min in group II with mean time 195 min.

Table 3: Comparison between both groups according to T test.

	Group	N	Mean	Std. Deviation	Std. Error Mean
Age	Study Group	10	58.8	11.71703	3.70525
	Control Group	10	59.8	10.48597	3.31595
Blood loss	Study Group	10	117.6	38.81351	12.27391
	Control Group	10	165	34.07508	10.77549
Duration of procedure	Study Group	10	157	10.5935	3.34996
	Control Group	10	186	10.74968	3.39935

T test was used to estimate the differences between both groups according to age of patients, duration of operating time and amount of blood loss (Table 3).

The electromyographic activities were recorded one day before surgery and three months after surgery and the data was expressed as mean differences between these two records, so that any increase in this difference denotes reduction in the electromyographic activities in the second record and vice versa. Comparison between the mean differences in the electromyographic activities of the masseter and temporalis muscles on both sides was statistically evaluated in both groups, using a two-way Analysis Of Variance (ANOVA) with repeated measures.

During clenching, a highly significant decrease was observed in the recorded electomyographic activities at the second record, regarding the mean voltage, RMS and power values for patients of group II on both the intact and surgical sides. This difference was statistically significant between group I and group II ($P<0.001$) (Table 4,5, Figure 9).

Similarly, during chewing soft food, a highly significant decrease was observed in the recorded electomyographic activities at the second record, regarding the mean voltage, RMS and power values, for patients of group II on both the intact and surgical sides. This difference was statistically significant between group I and group II ($P<0.001$) (Table 6,7, Figure 10).

Discussion

A maxillary-palatal defect may have serious consequences as far as concerns the relationship between form and function: inability to chew and swallow disorders in phonation and important psychological implications. The jaw has a functional and aesthetic role. Functionally, palatal bone separates the oral cavity from the nasal fossa and occlusion between the dental arches provides the

Table 4: The mean differences between the two records of the electromyographic activities of the masseter and temporalis muscles during clenching for both groups.

	Surgical side						Intact side					
	Masseter m			Temporalis m			Masseter m.			Temporalis m.		
	MV	RMS	P	MV	RMS	P	MV	RMS	P	MV	RMS	P
Difference between group I & II n	0.029*	0.056*	0.107*	0.046*	0.102*	0.11*	0.024*	0.07*	0.08*	0.048*	0.04*	0.087*
LSD	0.009	0.017	0.057	0.012	0.047	0.035	0.009	0.009	0.005	0.018	0.019	0.019

*P values <0.001 were considered highly significant

Table 5: The Least Significant Difference values (LSD) for the differences between group I and II during clenching:

	Surgical side						Intact side					
	Masseter m			Temporalis m			Masseter m.			Temporalis m.		
	MV	RMS	P	MV	RMS	P	MV	RMS	P	MV	RMS	P
Group I	0.003± 0.002	0.004±0.002	0.033 ± 0.002	0.014± 0.005	0.018 ± 0.008	0.05 ± 0.016	0.008± 0.002	0.01 ± 0.003	0.03 ± 0.011	0.022± 0.008	0.032± 0.008	0.035± 0.003
Group II	0.032± 0.008	0.06 ± 0.016	0.14 ± 0.055	0.06 ± 0.01	0.12 ± 0.045	0.16 ± 0.008	0.032± 0.008	0.08 ± 0.008	0.11 ± 0.017	0.07 ± 0.016	0.072± 0.016	0.122± 0.018

Table 6: The mean differences between the two records of the electromyographic activities of the masseter and temporalis muscles during chewing soft food for both groups.

	Surgical side						Intact side					
	Masseter m			Temporalis m			Masseter m.			Temporalis m.		
	MV	RMS	P	MV	RMS	P	MV	RMS	P	MV	RMS	P
Group I	0.006± 0.002	0.006± 0.001	0.008± 0.001	0.001± 0.001	0.006± 0.002	0.009± 0.002	0.011± 0.001	0.018± 0.002	0.031± 0.002	0.001± 0.001	0.009± 0.002	0.024± 0.002
Group II	0.014± 0.002	0.017± 0.068	0.032± 0.002	0.022± 0.008	0.032± 0.002	0.04 ± 0.007	0.033± 0.003	0.046± 0.001	0.065± 0.003	0.026± 0.001	0.035± 0.002	0.12 ± 0.016

Table 7: The Least Significant Difference values (LSD) for the differences between group I and II during chewing soft food:

	Surgical side						Intact side					
	Masseter m			Temporalis m			Masseter m.			Temporalis m.		
	MV	RMS	P	MV	RMS	P	MV	RMS	P	MV	RMS	P
Difference between group I & II	0.008*	0.011*	0.024*	0.021*	0.026*	0.031*	0.022*	0.028*	0.034*	0.025*	0.026*	0.096*
LSD	0.002	0.002	0.003	0.009	0.005	0.008	0.003	0.005	0.007	0.004	0.002	0.017

*P values <0.001 were considered highly significant

mandible with the stability which enables the pharyngeal muscles to initiate the critically important act of swallowing. Aesthetically, the maxillary bone is responsible for the projection of the nose, cheeks and hemi-face, also dention in maxilla have important role in masticatory muscle coordination [12].

Most of malignant tumors in maxilla and hard palate are diagnosed late, when they invade the underlying bone. Which make the Patients are prone to many problems, including bleeding, infection, fistula, and uncontrollable pain. Massive hemorrhage is the most serious and immediate of these complications [13].

To meet the fundamental objective of management of malignant maxillary and hard palate tumors with reduce of bleeding and totally eradication of tumor with safety margin and immediate restore the function and aesthetic was our aim in this study.

Bleeding from an unresectable or advanced, local recurrent malignancies of the head and neck, which can occur either from the tumor bed or from erosion into a large vessel, represents a difficult management problem [14]. Past management of tumor hemorrhage has included ligation of the carotid artery and transarterial embolization using Polyvinyl Alcohol (PVA) and a detachable balloon [13-17].

Ligation of the External Carotid Artery (ECA) is a relatively simple procedure with minimal morbidity; however, its efficacy in arresting ongoing blood loss is questionable. It was reported to be successful in 2 of 3 cases of hemorrhage after Le Fort osteotomy [18] in 4 of 5 patients having hemorrhage during mandibular osteotomies [19] 20 and in bleeding after temporomandibular joint surgery [20].

There is difficult to identify regional lymph node metastasis based on clinical parameters alone also some cases showed regional lymph node metastasis even though, the radiographic examination and final needle aspiration showed free lymph node involvement. A lot of surgeons give little attention to clinically negative lymph node in neck when compare with other oral cavity tumors. Therefore, a selective neck dissection is commonly recommended for patients with maxillary tumors [3].

The traditional treatment sequence for patient requiring a maxillectomy is the initial insertion of an immediate surgical obturator at the time of surgery or soon thereafter, an interim obturator used after initial healing until the tissues are stabilized (approximately 3 months) and definitive obturator prepared after the tissue have stabilized, with few appreciable changes [21]. The suggested design of the obturator allowed it to act as an immediate/interim obturator as it provided a faster adaptation of the patient to the new situation. In addition, it avoided the patient from making impressions in the painful post-surgical phase for construction of an interim obturator. It allowed for replacement of the anterior teeth and maxillary arch form for better esthetics, and thus, greatly alleviating the physiologic and psychologic shock of the patient after maxillectomy. The use of a buccal-retaining flange ensured adequate retention and better

restoration of different functions such as deglutition and phonetics.

One of the greatest advantages of the proposed design is that the palatal contours are less bulky and located more superiorly in the patient's mouth because of proper cast modification before construction of the suggested obturator. This modification helped the patient to function properly during deglutition and speech. However, with the other design, all patients complained of excessive bulk of the palatal contour and difficulty in deglutition and speech [8].

The reduction in the electromyographic activity on the intact side after surgery is also significantly less with the suggested design of obturator may be related to the ability of the patients to function more properly with such obturator.

The construction of the obturator with a hollow bulb minimized the weight of the obturator as it reduces the amount of compound used to restore the facial contours. This minimizes the stresses on the teeth on the intact side as it utilizes the buccal soft tissue undercut together with the teeth undercuts for providing retention [22].

The presence of artificial posterior teeth ensured a situation closely resembling the pre-surgical phase. The tongue and lips can maintain a satisfactory anatomic relationship with the teeth and palate, thus enabling the patient to perform nearly normal eating, swallowing and speaking. Thus, the addition of posterior teeth together with the anterior teeth ensured better adaptation and better phonetics. This explains why the proposed design minimized the dramatic reduction in the muscular activities of the masticating muscles that usually occurs post-surgically as compared to the conventional obturator design [23].

In addition, many benefits of the proposed design were noticed, including reduction of the psychological impact on the patient, better restoration of the facial contours, better retention and stability during function, in addition to, preservation of the different functions as deglutition and phonetics [24].

It is worth to mention that the electromyographic activity was recorded before surgery while the patient was using the non-surgical side for mastication to be able to compare these readings with the second electromyographic readings, where the patients were allowed only to utilize the non-surgical side for mastication.

For patients of group II, although the obturator restored the palatal contours, the great amount of compound used to restore the facial contour increased the weight of the obturator with a lot of discomfort during use, in addition to the absence of posterior teeth. This explains the highly significant decrease in the recorded electromyographic activities of these patients compared to those of group I after surgical resection on both the surgical and intact sides.

During clenching as well as chewing soft food, the differences in the recorded electromyographic activities were highly significant in patients of group II on both the surgical and intact sides, as the difference between two designs is not only related to the shape of the immediate obturator on the surgical side, but also to the means of retention used for both designs.

Conclusion

Temporary vascular control of external carotid artery showed clean surgical field during maxillectomy that facilitate check margin of surgical ablation from any residual lesion, also reduce time waste of obturator adjustment. Design of obturator in group I showed more muscle activity and improve of psychological aspect of the patients.

References

1. Tirelli G, Rizzo R, Biasotto M, Di Lenarda R, Argenti B, Gatto A, et al. Obturator prostheses following palatal resection: clinical cases. Acta Otorhinolaryngol Ital. 2010;30(1):33-9.
2. Omondi BI, Guthua SW, Awange DO, Odhiambo WA. Maxillary obturator prosthesis rehabilitation following maxillectomy for ameloblastoma: case series of five patients. Int J Prosthodont. 2004;17(4):464-8.
3. Montes DM, Carlson ER, Fernandes R, Ghali GE, Lubek J, Ord R, et al. Oral maxillary squamous carcinoma: an indication for neck dissection in the clinically negative neck. Head Neck. 2011;33(11):1581-5.
4. Huryn JM, Piro JD. The maxillary immediate surgical obturator prosthesis. J Prosthet Dent. 1989;61(3):343-7.
5. Garg AK, Malo M, Dorado LS, Duarte F. Postsurgical management with maxillary obturators after maxillectomy. Gen Dent. 1998;46(1):75-8.
6. Beumer J, Curtis TA, Marunick MT. Maxillofacial rehabilitation. Prosthodontic and Surgical Consideration. Ishiyaku Euro America, Inc. Publishers. St. Louis, Tokyo. 1996;240-7.
7. Kornblith AB, Zlotolow IM, Gooen J, Huryn JM, Lerner T, Strong EW, et al. Quality of life of maxillectomy patients using an obturator prosthesis. Head Neck. 1996;18(4):323-34.
8. Lapointe HJ, Lampe HB, Taylor SM. Comparison of maxillectomy patients with immediate versus delayed obturator prosthesis placement. J Otolaryngol. 1996;25(5):308-12.
9. Cordeiro PG, Santamaria E, Kraus DH, Strong EW, Shah JP. Reconstruction of total maxillectomy defects with preservation of the orbital contents. Plast Reconstr Surg. 1998;102(6):1874-84.
10. Maire F, Kreher P, Toussaint B, Dolivet G, Coffinet L. Prosthesis fitting after maxillectomy: an indispensable factor in acceptance and rehabilitation. Rev Stomatol Chir Maxillofac. 2000;101(1):36-8.
11. Fandino TL, Lopez PR. Fabrication of surgical obturator (immediate prosthesis) in a patient with hemimaxillectomy for epidermoid carcinoma. Rev ADM. 2001;58:220-8.
12. Genden EM, Okay D, Stepp MT, Rezaee RP, Mojica JS, Buchbinder D, et al. Comparison of functional and quality-of-life outcomes in patients with and without palatomaxillary reconstruction: a preliminary report. Arch Otolaryngol Head Neck Surg. 2003;129(7):775-80.
13. Bhansali S, Wilner H, Jacobs JR. Arterial embolization for control of bleeding in advanced head and neck carcinoma. J Laryngol Otol. 1986;100(11):1289-93.
14. Wilner HI, Lazo A, Metes JJ, Beil KA, Nowack P, Jacobs J. Embolization in cataclysmal hemorrhage caused by Squamous cell carcinomas of the head and neck. Radiology. 1987;163(3):759-62.
15. Feifel H, Volle E, Riediger D, Gustorf-Aeckerle R. Superselective embolization in an errosive haemorrhage of a carcinoma in the parotid gland. Int J Oral Maxillofac Surg. 1991;20(6):369-70.
16. Morrissey DD, Andersen PE, Nesbit GM, Barnwell SL, Everts EC, Cohen JI. Endovascular management of hemorrhage in patients with head and neck cancer. Arch Otolaryngol Head Neck Surg. 1997;123(1):15-9.
17. Kaufinan SL. Simplified method of transcatheter embolization with polyvinyl alcohol foam (Ivalon). AJR Am J Roentgenol. 1979;132(5):853.
18. Lanigan DT, West RA. Management of postoperative hemorrhage following Le Fort I maxillary osteotomy. J Oral Maxillofac Surg. 1984;42(6):367-75.
19. Lanigan DT, Hey J, West RA. Hemorrhage following mandibular osteotomies: A report of 21 cases. J Oral Maxillofac Surg. 1991;49(7):713-24.

20. Vallerand WP, Dolwick MF. Complications of temporomandibular joint surgery. Oral Maxillofac Surg Clin North Am. 1990;2:481.

21. Rodrigues SJ, Saldanha S. Prosthetic rehabilitation of a patient after partial maxillectomy: A clinical report. Contemp Clin Dent. 2011;2(4):355-8.

22. Benington IC, Cunningham JL. Sorption determination of hollow VLC resin obturators. J Prosthet Dent. 1998;80:129-32.

23. Patil PG. Surgical obturator duplicating original tissue-form restores esthetics and function in oral cancer. World J Stomatol. 2013;2(4):97-102.

24. Türkaslan S, Baykul T, Aydın MA, Ozarslan MM. Influence of immediate and permanent obturators on facial contours: a case series. Cases J. 2009;2(1):6.